



Clinical Outcome of Intravascular Ultrasound Guided Left Main Coronary Intervention

Mohamed Ezzelregal^{1*}, Luca Testa², Medhat Alashmawy¹, Ayman Elsaid¹ and Hanan Kassem¹

¹Department of Cardiology, Tanta University Hospital, Tanta, Egypt.

²Department of Cardiology, IRCCS Policlinico S. Donato, San Donato M.ne, Milan, Italy.

Authors' contributions

This work was carried out in collaboration among all authors. Authors ME and MA designed the study, performed the statistical analysis, wrote the protocol and wrote the first draft of the manuscript. Authors LT and AE managed the analyses of the study. Author HK managed the literature searches. All authors read and approved the final manuscript.

Article Information

DOI: 10.9734/JAMMR/2020/v32i1330552

Editor(s):

(1) Dr. Pietro Scicchitano, Italy.

Reviewers:

(1) Mohamed Salah Eldin Zaki ElRamly, Cairo University, Egypt.

(2) Chandra Mani Poudel, Tribhuvan University, Nepal.

Complete Peer review History: <http://www.sdiarticle4.com/review-history/59665>

Review Article

Received 02 June 2020

Accepted 08 August 2020

Published 14 August 2020

ABSTRACT

Introduction: Intravascular ultrasound is a new imaging modality that facilitate the process of coronary intervention. The angiographic evaluation of left main lesions significance is always questionable, IVUS detect the significance, guide the procedure and some studies proves a benefit in mortality.

Objectives: To investigate whether intravascular ultrasound IVUS guided Left Main coronary intervention could improve clinical outcomes compared with angiographic-guided Left main coronary PCI.

Patients and Methods: This controlled study was carried out between June 2017 and June 2019, in Tanta university Hospital and San Donato Hospital, Milan, 83 patients eligible to Left Main coronary intervention divided into two groups, IVUS-guided group (n=19) and angiographic-guided group(n=64). The occurrence of major adverse cardiac events (MACE): death, non-fatal myocardial infarction, or target lesion revascularizations) were recorded 6 and 18 Months of follow-up.

*Corresponding author: E-mail: moh.ezzelregal.86@gmail.com;

Results: The IVUS-guided group had a lower rate of 18-months MACE than the control group. The incidence of target lesion revascularization was lower in the IVUS-guided group than in the control group. The incidence of TLR after 6 months was not different between both groups (1 cases in IVUS group (5.3%), 6 cases in angiography group (9.4%) (P value 0.686) while the incidence of TLR after 18 months was significantly different between both groups (1 cases in IVUS group (5.3%), 17 cases in angiography group (26.6%) (P value 0.048), However, there were no differences in death, myocardial infarction, stent thrombosis and number of patients treated with CABG in the 2 groups.

Conclusion: The present study demonstrates that IVUS-guided LM angioplasty can improve 18 - months MACE events especially the incidence of target lesion revascularization.

Keywords: Coronary artery disease; intravascular ultrasound; percutaneous coronary intervention; Major Adverse Cardiac Events (MACE).

1. INTRODUCTION

Percutaneous coronary intervention (PCI) for unprotected left main coronary arterial (ULMCA) stenosis is now rapidly emerging as a viable alternative to coronary artery bypass grafting (CABG). The accurate identification of significant stenosis of left main coronary artery (LMCA) is of critical importance [1].

Because of the limitations on the assessment of the severity of left main coronary artery (LMCA) stenosis, intravascular ultrasound imaging allows more accurate assessment of the morphology of the disease and the significance in often complex coronary angiograms [2].

The use of intravascular ultrasound (IVUS) guided Left Main (LM) interventions has been advocated as a means to optimize procedural results with the hope that this may translate into improved long-term clinical outcomes. [3]

Better angiographic results are undebatable with the guidance of IVUS but short- and long-term benefits regarding the clinical outcome were attractive to many researchers, in our study, we studied the of MACE events in patient who received IVUS guidance during Left Main PCI comparing them to another group treated with conventional coronary intervention with no IVUS use.

2. METHODS

The design of the current study is a prospective cohort study with control group, this intervention observational study was conducted on 83 patients who were prepared for elective Left main coronary intervention and stenting in cardiology department of Tanta university hospital and cardiology department of San Donato hospital,

Milan. The study was conducted from June 2017 to June 2019.

2.1 Inclusion Criteria

1. Patient is ≥ 20 years or ≤ 80 years old
2. Significant Left main coronary stenosis eligible for PCI after Heart Team Discussion
3. Patients who can keep the dual antiplatelet treatment (aspirin, clopidogrel) more than 6 months after procedure

2.2 Exclusion Criteria

1. Unsuccessful coronary angioplasty procedure
2. Contraindication to aspirin, clopidogrel.
3. Instant restenosis or graft occlusion
4. Creatinine level ≥ 3.0 mg/dL or ESRD
5. Severe hepatic dysfunction (3 times normal reference values)

All patients were subjected to thorough history taking, complete clinical examination, laboratory investigations including:

- Serum creatinine, blood urea.
- Liver function tests
- Lipid profile
- CBC
- Prothrombin time and INR

All patient had ECG done and examined by echo-cardiography.

2.3 Procedure

Coronary angiography was performed in the 2 groups via a trans radial or transfemoral approach. All procedures were performed

according to the current PCI guidelines. Unfractionated heparin was used during the procedure according to body weight and ACT. A loading dose of aspirin (300 mg) and clopidogrel (600 mg, or ticagrelor with 180 mg) were recommended for all patients. After PCI, all patients were prescribed aspirin 100 mg daily indefinitely and clopidogrel 75 mg daily (ticagrelor 90 mg twice a day) for at least 12 months. After coronary angiography, patients with no exclusion criteria and eligible to PCI were divided into two groups:

The first group (19 patients performed in San Donato hospital, Milan) In the IVUS group, the stenting technology was decided based on both angiographic finding and IVUS finding.

2.4 Intravascular Ultrasound Technique

IVUS allows assessment of the morphology and composition of coronary atheroma, enable the luminal area, diameter, and degree of area stenosis to be calculated accurately, and provides images of the entire left main stem including the ostium, body and bifurcation.

Our practice to use 40 mhz Mechanical probe system which provides good resolution for left main stem (opticross [I-Lab, Boston Scientific Corp/SCIMED, Minneapolis, MN] or Eagle Eye [Volcano Therapeutics, Rancho Cordova, CA]. All IVUS images were stored on to a DVD thereafter for off-line measurements

The IVUS probe is advanced over the guide wire into LAD or CX at least 10 mm distal to the Left main lesion. Following intracoronary administration of nitroglycerin (100 to 200 mg). IVUS probe is withdrawn with the aid of an automated pullback device at 0.5mm/sec through the left main stem to aortic root.

The guide catheter should be fully disengaged during this process to ensure that a complete study is made of the entire left main stem and its ostium. The guide catheter and guide wire should be maintained in a position coaxial to the main stem to minimize wire artifact.

IVUS run was done post stenting also to detect mal-apposition, incomplete lesion coverage and edge dissection and being managed thereafter.

The second group (59 patients performed in Tanta university hospital), In the angiography-guided group, Minimal lumen diameter (MLD)

and lesion length were measured with the quantitative coronary angiography (QCA).

In the control group, the intervention strategy was decided based on the location of the lesion. Stent diameter and length were selected by visual estimation with the ratio of stent/vessel diameter of 1.1:1.0. Post dilation with a noncompliant balloon was not routine and was done according to the operator experience, the result of the stents was checked angiographically.

2.5 Strategy and Technique of Left Main Stenting

Our treatment strategy of LM stenting in both groups is the approach suggested by the European Bifurcation Club that recommends a provisional stenting approach in most cases of distal bifurcation LMCA especially in simple LM bifurcation and two stent technique in complex LM bifurcation followed by kissing balloon inflation (whether TAP, Culotte and preferably D-K crush techniques)

FOLLOW-UP. After hospital discharge, clinical follow-up was performed with office visits (preferred) at 6 and 18 months, careful inquiring about symptoms and events or hospital admission due to any cause were done, full clinical examination and 12 leads ECG and echocardiography were done at each visit, Angiographic follow up was repeated for some cases with recurrence of symptoms.

2.6 Statistical Analysis

Statistical presentation and analysis of the present study was conducted, using the mean, standard deviation and chi-square test by SPSS V.22.

3. RESULTS

3.1 Patients' Characteristics

The basic Baseline characteristics obtained for patients included in the study are outlined in Fig. 1.

Regarding sex distribution, the study included 64 males (77.1%) and 19 females (22.9%). IVUS group included 12 males and 7 females, while Angiographic group included 52 males and 12 females. There were no significant differences between groups as regards sex ($P=0.12$). Other baseline characters are shown in Table 2.

The mean Age of the study population = 67.27±11.26. Their age in IVUS group ranged from 43 to 77 years with a mean age value of (61.947 ±9.4), while their age in Angiographic group ranged from 43 to 87 years with a mean age of (68.85± 11.35). There was a significant difference between groups as regards age (P=0.011). Other demographic data are shown in Table 1.

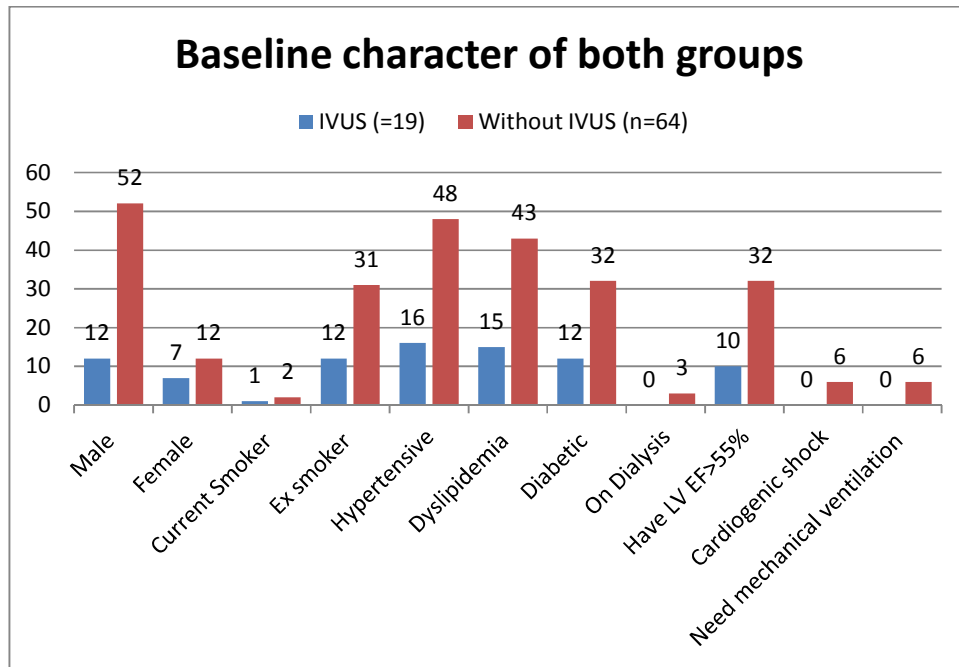


Fig. 1. Baseline character of both groups

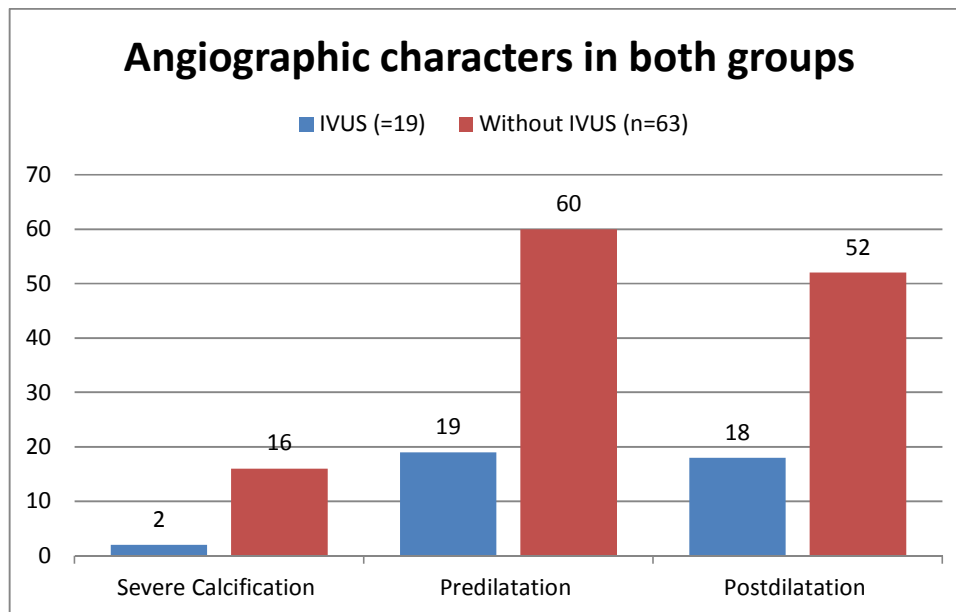


Fig. 2. Angiographic characters in both groups

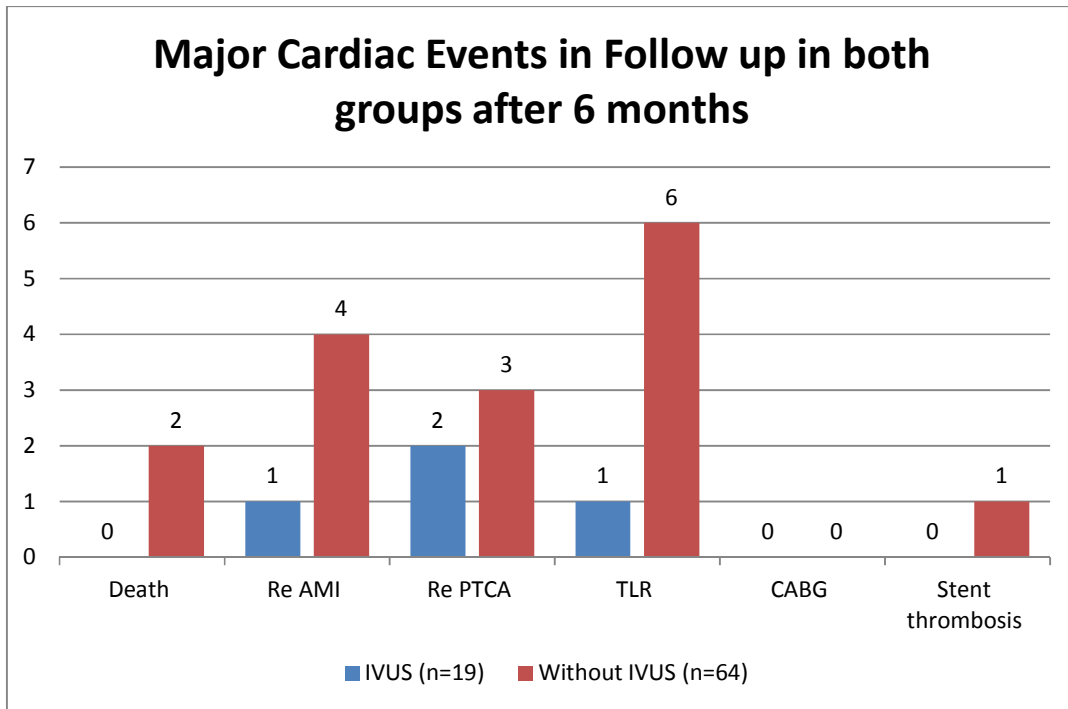


Fig. 3. Major cardiac events in both groups after 6 months

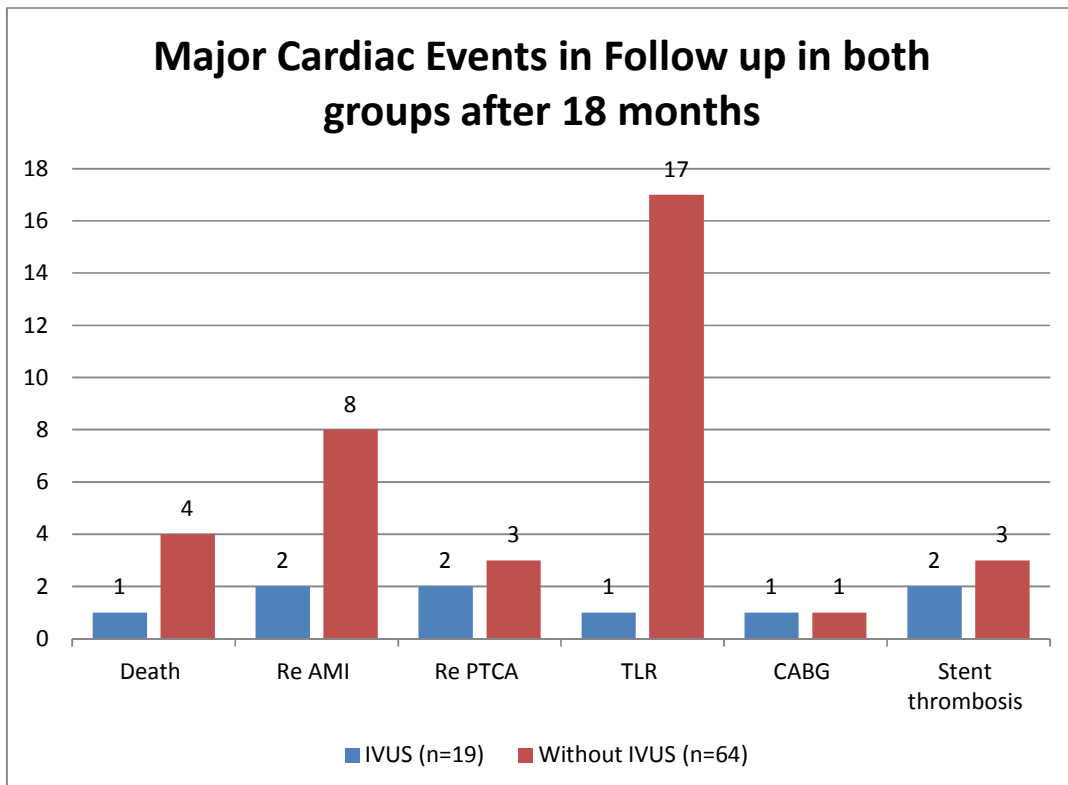


Fig. 4. Major cardiac events in both groups after 18 months

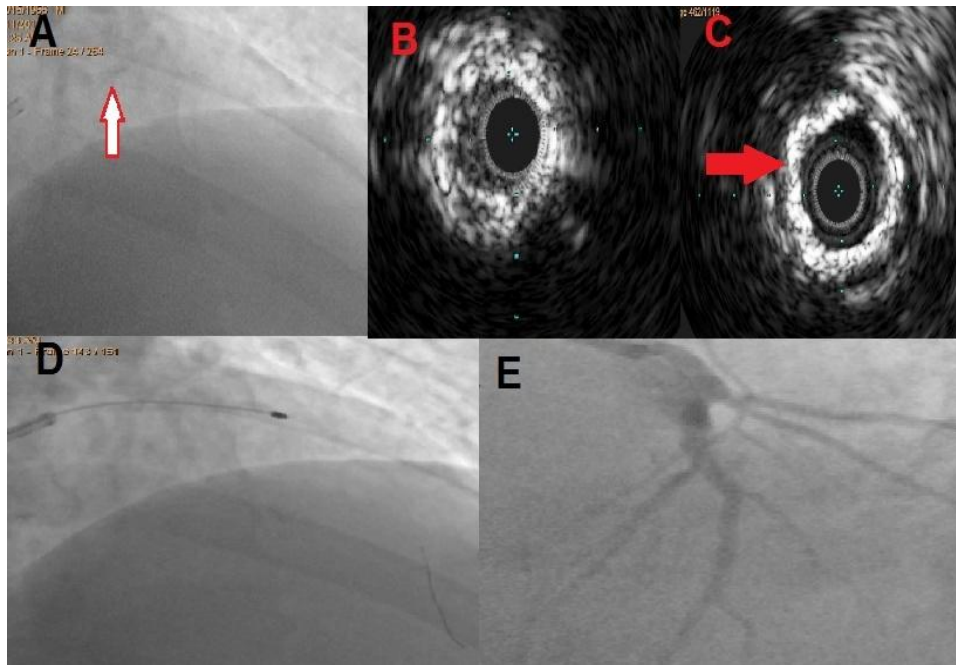


Fig. 5. A case of IVUS guidance for assessment of calcium and Rotablator use A) arrow shows faint shadow of calcification, B) Calcium absorb echo waves hiding all behind C) clear circumferential calcium D) rotablator used E) good final result

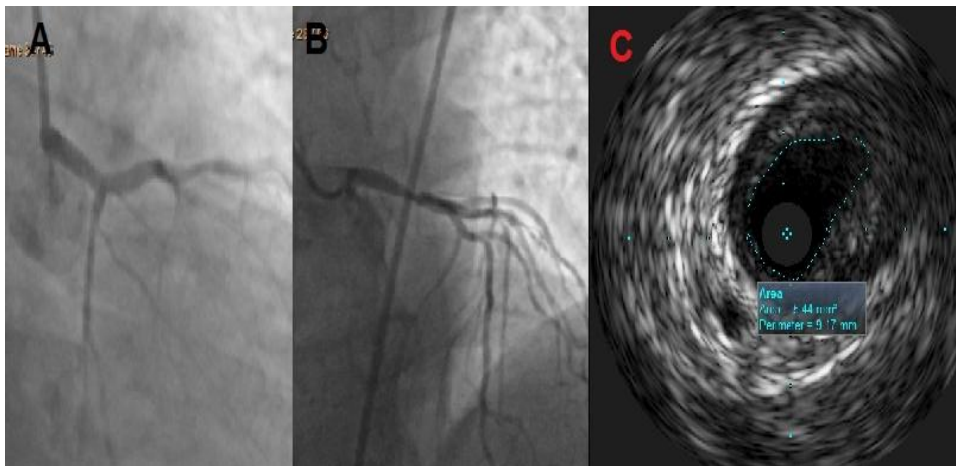


Fig. 6. A case of IVUS role to determine the significance of borderline LM lesion A) Caudal view showing non-significant LM lesion distally, B) cranial view raising the suspicion C) IVUS measured MLA about 5.4 mm²

Table 1. Demographic data and creatinine level

	Mean	±	SD	Min	Max
Age at procedure (83)	67.27	±	11.26	43	87
Height (cm) (83)	168.63	±	4.93	150	185
Weight (kg) (83)	71.27	±	9.11	44	114
Creatinine (mg/dL) (83)	1.27	±	1.135	0.6	7

Table 2. Incidence of baseline characters in both groups

		IVUS (=19)	Without IVUS (n=64)	χ^2	P value
Sex (83)	Female	7	12	2.716	0.12 ^a
	Male	12	52		
Smoking (82)	Current	1	2	1.732	0.513 ^b
	No	6	30		
	Ex	12	31		
Hypertension (83)	Yes	16	48	0.704	0.54 ^a
	No	3	16		
Dyslipidemia (83)	Yes	15	43	0.963	0.403 ^a
	No	4	21		
Diabetes (83)	Yes	12	32	1.01	0.433 ^a
	No	7	32		
Dialysis (83)	Yes	0	3	0.924	0.583 ^a
	No	19	61		
LVEF>55% (83)	Yes	10	32	0.04	1.0 ^a
	No	9	32		
Cardiogenic shock (83)	Yes	0	6	1.92	0.328 ^a
	No	19	58		
Need of mechanical circulatory support (83)	Yes	0	6	1.92	0.328 ^a
	No	19	58		

a: P value was calculated by Fisher's Exact test b: P value was calculated by Monte Carlo test

Table 3. Angiographic characters in both groups

		IVUS (=19)	Without IVUS (n=64)	χ^2	P value
Severe calcification (83)	Yes	2	16	1.807	0.221 ^a
	No	17	48		
Pre-dilation (83)	Yes	19	60	1.248	0.569 ^a
	No	0	4		
Post-dilation (83)	Yes	18	52	2.01	0.28 ^a
	No	1	12		

a: P value was calculated by Fisher's Exact test

Table 4. Syntax score in both groups

Syntax Score (83)	IVUS (n= 19)			Without IVUS (n=64)			T test	P Value
	Mean	±	SD	Mean	±	SD		
	30.08	±	10.72	31.82	±	10.92	-0.619	0.54
Range	11 - 56			10 -72				

3.2 Procedural Details

3.2.1 Angiographic characters in both groups

Among the studied populations, 18 patients had severe calcification (21.7%). In IVUS group, there were 2 patients with severe calcification while in angiographic group, there were 16 patients with severe calcification. There were no significant differences between groups as regards severe calcification (P= 0.221).

Among the studied populations, 79 patients (95.2%) underwent predilatation of lesion, All

patients (19 patients) that involved in IVUS group underwent predilatation while most of patients (60 patients) that involved in angiographic group underwent predilatation. There were no significant differences between groups as regards predilatation (P= 0.569).

3.3 Procedural Details

3.3.1 Angiographic characters in both groups

Among the studied populations, 18 patients had severe calcification (21.7%). In IVUS group, there were 2 patients with severe calcification while in angiographic group, there were 16

patients with severe calcification. There were no significant differences between groups as regards severe calcification (P= 0.221).

Among the studied populations, 79 patients (95.2%) underwent predilatation of lesion, All patients (19 patients) that involved in IVUS group underwent predilatation while most of patients (60 patients) that involved in angiographic group underwent predilatation There were no significant differences between groups as regards predilatation (P= 0.569).

As regarding Stent post dilatations, 70 patients (85.4%) underwent postdilatation of the stent. In IVUS group, there were 18 patients underwent stent post dilatation while in angiographic group, there were 52 patients underwent stent post dilatation. There were no significant differences between groups as regards postdilatation (P= 0.28). angiographic characters are shown in Table 3.

As regarding Stent post dilatations, 70 patients (85.4%) underwent postdilatation of the stent. In

IVUS group, there were 18 patients underwent stent post dilatation while in angiographic group, there were 52 patients underwent stent post dilatation. There were no significant differences between groups as regards postdilatation (P= 0.28). angiographic characters are shown in Table 3.

3.3.2 Syntax score

The mean value of syntax score of the study population =31.43±10.83. Their syntax score in IVUS group ranged from 11-56 with a mean value of (30.08 ±10.72) while their syntax score in Angiographic group ranged from 10-72 with a mean value (31.82± 10.92). There were no significant differences between groups as regards syntax score (P=0.54)

3.3.3 Intravascular Ultrasound (IVUS) characteristics of IVUS guided group

MLD - minimal lumen diameter, MLA - minimal lumen area, MSD - minimal stent diameter, MSA - minimal stent area.

Table 5. Intravascular ultrasound (IVUS) characteristics of IVUS guided group

	IVUS group (n=19) Mean±SD
MLD (mm)	2.05±0.33
MLA (mm ²)	4.74±0.82
Plaque burden (%)	67.16±8.21
Expansion ratio	0.93±0.05
Post-stent MSD (mm)	3.55±0.16
Post-stent MSA(mm ²)	10.80±1.42

Table 6. Incidence of major cardiac events in follow up in both groups after 6 months

	IVUS (N=19)	Without IVUS (N=64)	x ²	P value
Death 6 months	0 (0 %)	2 (3.1 %)	0.608	1
ReAMI 6 months	1 (5.3 %)	4 (6.3 %)	0.025	1
RePTCA 6 months	2 (10.5 %)	3 (4.7 %)	0.882	0.584
TLR 6 months	1 (5.3 %)	6 (9.4 %)	0.321	0.686
CABG 6 months	0 (0 %)	0 (0 %)		
Stent thrombosis 6 months	0 (0 %)	1 (1.6%)	0.3	1

Table 7. Incidence of major cardiac events in follow up in both groups after 18 months

	IVUS (N=19)	Without IVUS (N=64)	x ²	P value
Death 18 months	1 (5.3 %)	4 (6.3 %)	0.025	1
Re AMI 18 months	2 (10.5 %)	8 (12.5 %)	0.054	1
RePTCA 18 months	2 (10.5 %)	3 (4.7 %)	0.882	0.584
TLR 18 months	1 (5.3 %)	17 (26.6 %)	0.159	0.048
CABG 18 months	1 (5.3 %)	1 (1.6%)	0.853	0.408
Stent thrombosis 18 months	2 (10.5 %)	3 (4.7 %)	0.882	0.584

3.4 Analysis of the Results

3.4.1 Follow up of adverse MACE after 6 months

Two patients died within 6 months after the procedure, the incidence of cardiac mortality after 6 months was not different between both groups (No cases in IVUS group (0%), 2 cases in angiography group (3.1%) (P value =1). Five patients developed AMI within 6 months after the procedure, the incidence of AMI after 6 months was not different between both groups (1 case in IVUS group (5.3%), 4 cases in angiography group (6.3%) (P value=1). Five patients underwent RE PTCA, the incidence of REPTCA after 6 months was not different between both groups (2 cases in IVUS group (10,5%), 3 cases in angiography group (4.7%) (P value 0.584).

Seven patients underwent TLR, the incidence of TLR after 6 months was not different between both groups (1 case in IVUS group (5.3%), 6 cases in angiography group (9.4%) (P value 0.686).

Stent thrombosis developed in one patient (1.6%) in the angiographic group with no significant different between both groups as regard stent thrombosis after 8 months follow up, (P value 1).

No patients underwent CABG in both groups with no significant different between both groups after 8 months follow up.

3.4.2 Follow up of adverse MACE after 18 months

Five patients died within 18 months of the procedure, the incidence of cardiac mortality after 18 months was not different between both groups (one case in IVUS group (5.3%), 4 cases in angiography group (6.3%) (P value1).

Ten patients developed AMI within 18 months after the procedure, the incidence of AMI after 18 months was not different between both groups (2 cases in IVUS group (10.5%), 8 cases in angiography group (12.5%) (P value 1).

Five patients underwent REPTCA, the incidence of REPTCA after 18 months was not different between both groups (2 cases in IVUS group (10,5%), 3 cases in angiography group (4.7%) (P value 0.584).

Eighteen patients underwent TLR, the incidence of TLR after 18 months was significantly different

between both groups (1 case in IVUS group (5.3%), 17 cases in angiography group (26.6 %) (P value 0.048).

Stent thrombosis developed within 18 months in two patients (10.5%) in IVUS group while in angiographic group developed in three patients (4.7%) with no significant different between both groups as regard stent thrombosis after 88 months follow up, (P value 0.584).

No patients underwent CABG in both groups with no significant different between both groups after 8 months follow up.

Case No 1 Angiography of this case doesn't give the impression of heavy calcification in distal Left main-Ostial LAD revealed by IVUS, IVUS showed complete calcium arc, decision was changed from scoring balloon to rotablator which allowed good expansion of the stents.

Case No 2 The patient has angiographically borderline left main lesion that can be easily missed and left untreated but IVUS declared the significance by measuring MLA of 5.4 mm².

4. DISCUSSION

The evolution of intravascular ultrasound is an important landmark in the field of coronary intervention; it solved many of the angiographic limitation such as assessment of severity of lesions with its marked intra- and inter-observer variability, vessel and lumen dimensions, plaque characteristics and assessment of stents results. [4].

It is important to define what is meant by IVUS guided angioplasty, as the success of IVUS to achieve better results depend on achieving the IVUS defined criteria, selection of stent diameter and length must be IVUS driven, some debate was is to choose the stent diameter equal to the distal reference segment diameter or the mean of proximal and distal reference segment, the length of the stent is easily extracted from IVUS data analysis after automatic pull back by Landing proximally and distally in nearly healthy segments with plaque burden less than 50%. [5].

This prospective observational study included 83 patients eligible to LM PCI and divided in 2 different groups (IVUS guided) (angiographic guided) so, we can follow up adverse MACE in each group separately and also, we compare both groups as regards MACE 6,18 months follow up after LMPCI.

The aim of this work was to compare clinical outcomes of IVUS guided Left main coronary angioplasty versus angiographic guided Left Main coronary angioplasty, regarding the incidence of Major Adverse Cardiac Events (death, non-fatal -myocardial infarction, target vessel revascularization), the study is trying to investigate the impact of IVUS not on the acute angiographic improvement but on the short term clinical outcome over 6,18 months of follow up,

4.1 IVUS Guided Group (n = 19 Patients)

The follow up of adverse MACE in of IVUS guided group included , No cases died (0%) after 6 months while one case died (5.3%) within 18 months, 1 case developed AMI (5.3%) after 6 months while, 2 cases developed AMI (10.5%) within 18 months , 2 cases underwent RE PTCA (10,5%) after 6 months while 2 cases underwent RE PTCA (10,5%) within 18 months, 1 case (5.3%) underwent TLR after 6 months while 1 cases underwent TLR (5.3%) within 18 months, No cases underwent CABG (0%) after 6 months and 1 case underwent CABG within 18 months (5.3%), No cases developed stent thrombosis (0%) after 6 months while, two patient (10.5%) developed Stent thrombosis within 18 months.

4.2 Angiographic Guided Group (n=64 Patients)

The follow up of adverse MACE in of Angiographic guided group included , 2 cases (3.1%) died after 6 months while 4 cases (6.3%) died within 18 months, 4 cases developed AMI (6.3%) after 6 months while , 8 cases in angiography group (12.5%) within 18 months , 3 cases (4.7%) underwent RE PTCA after 6 months while, 3 cases in angiography group (4.7%) underwent RE PTCA within 18 months, 6 cases in angiography group(9.4%) underwent TLR after 6 months while 17 cases in angiography group(26.6 %) underwent TLR within 18 months, No cases underwent CABG (0%) after 6 months and 1 case underwent CABG within 18 months (1.6%) one patient (1.6%) developed stent thrombosis after 6 months while, three patients (4.7%) developed Stent thrombosis within 18 months.

In comparison of both groups as regards adverse MACE follow up six, 18 months post LM interventions we concluded that,

- The incidence of cardiac mortality after 6, 18 months follows up was not different between both groups (p value = 1, P value = 1 respectively)

- The incidence of Acute myocardial infarction after 6,18 months follows up months was not different between both groups (p value = 1, P value = 1 respectively)
- 3-The incidence of REPTCA after 6, 18 months follow up was not different between both groups (p value = 0.584, P value = 0.584 respectively)
- The incidence of TLR after 6 months was not different between both groups (1 cases in IVUS group (5.3%), 6 cases in angiography group (9.4%) (P value 0.686) while the incidence of TLR after 18 months was significantly different between both groups (1 cases in IVUS group (5.3%), 17 cases in angiography group (26.6 %) (P value 0.048)
- The incidence of stent thrombosis after 6, 18 months follows up months was not different between both groups (p value = 1, P value = 0.584 respectively)
- No patients underwent of CABG after 6 follow up months of both groups with only one patient in each groups underwent CABG within 18 months (p 0.408) with no difference between both groups.

4.3 Evidence that Using IVUS Guidance during LMCA Interventions Improves Outcomes (Which of these Studies Match or Not Our Study)

A post-hoc analysis from the MAIN- COMPARE (Revascularization for Unprotected Left Main Coronary Artery Stenosis: Comparison of Percutaneous Coronary Angioplasty vs Surgical Revascularization) registry published in 2009 by park et al in which nonrandomized long-term clinical outcomes were evaluated in 975 patients. To account for the significant baseline differences between the 2 patient groups, propensity score matching was used to identify 201 “comparable” pairs of patients in each group. Kaplan-Meier incidence curves of log-rank 3-year outcomes revealed a significant lowering of the cumulative mortality rate within the IVUS-guided ULMCA PCI group receiving DES 4.7%(1.0-8.3%) compared with the angiography guided group 16.0%(7.5-24.6%) P= 0.048, on multivariate analysis in all-comers (those receiving bare-metal stent and DES), there was a strong trend toward a statistically significant reduction in the rate of death at 3 years these results are not matching our results regarding Mortality benefit [6].

Tan et al study, 2012 applied on 123 elderly patients (age >70) with ULMCA were randomized to the IVUS guidance intervention group (61) patients and the control group (62 patients) who underwent intervention with routine angiography [7,8].

The IVUS-guided group had a lower rate of 2-year MACE than the control group) 13.1% versus 29.3%, $p=0.031$. (The incidence of target lesion revascularization was lower in the IVUS-guided group than in the control group) 9.1% versus 24%, $p=0.045$. However, there were no differences in death and myocardial infarction in the 2 groups. These results are matching our study in adverse MACE follow up [7].

De la Torre et al 2014 performed a patient-level pooled analysis of 4 registries of patients with LM disease treated with DES in Spain 2 from nationwide (ESTROFA-Left Main and RENACIMIENTO [Registro Nacional Sobre el Tratamiento del Tronco Comu n]) and 2 from single centers (Bellvitge and Valdecilla) [8].

1,670 patients were included, and 505 patients (30.2%) underwent DES implantation under IVUS guidance (IVUS group). By means of the matching method, 505 patients without the use of IVUS during revascularization were selected (no-IVUS group). Survival free of cardiac death, myocardial infarction, and target lesion revascularization at 3 years was 88.7% in the IVUS group and 83.6% in the no-IVUS group ($p = 0.04$) for the overall population, and 90% and 80.7%, respectively ($p = 0.03$), for the subgroups with distal LM lesions. The incidence of definite and probable thrombosis was significantly lower in the IVUS group. This study is matching our results in reduction of TLR in IVUS group and not matching our study in Mortality and myocardial infarction Benefits [8].

In 2017 kim et al conducted a study for non-complex LM lesions treated with the single stenting technique, and showed no clinical difference through 3 years follow up concluding that Although IVUS guided PCI is the ideal strategy, angiography-guided PCI can be an option for LMCA PCI in some selected cases, the result of study for noncomplex LM does not match our results as regards reduction of TLR with IVUS guidance and match our study as regards mortality and myocardial infarction and

this can be explained by that in this this trial complex lesions which are the subset of lesions that gets higher benefits from IVUS derived decisions, non-complex lesions are to some extent logic not to differ in procedure steps by IVUS usage.[9].

In the same year a meta-analysis of 10 studies was performed by Ye et al indicating that IVUS guidance of LMCA stenting reduced the risk of all-cause mortality by 40% and cardiac death by 53% compared with conventional angiography-guided procedures, these data were supported by a complex lesion meta-analysis performed by Fan et al. these results are not matching our study as regards mortality benefit with IVUS guidance [10].

In SCAAR (Swedish Coronary Angiography and Angioplasty Registry) of 2468 patients of unprotected LMCA PCI between 2005 and 2014 show that IVUS guidance was used in 621 patients (25.2%). The IVUS group was younger (median age, 70 versus 75 years) and had fewer comorbidities but more complex lesions. IVUS was associated with larger stent diameters (median, 4 mm versus 3.5 mm). After adjusting for potential confounders, IVUS was associated with significantly lower occurrence of the primary composite end point of all-cause mortality, restenosis, or definite stent thrombosis [11].

The ULTIMATE trial which was published in December 2018 was discussing the question “is IVUS beneficial even in the outcome of simple lesions?”, it is a multicenter, prospective, randomized study designed to compare the efficacy and safety between IVUS-guided and angiography-guided second-generation DES implantation in all-comer patients with coronary artery disease with no specifications of the type of the lesions [5].

Our study matches with *ULTIMATE trial* results that demonstrated a significant reduction of target vessel failure at 12 months follow-up when PCI procedures were guided by IVUS, and also matches ULTIMATE trial in comparing cardiac death between the two groups in which the difference was not statically significant. Although the study proves benefits of all patients from IVUS guidance, Pre-specified subgroup analysis showed a tendency for patients with ACS or multivessel disease to possibly benefit from IVUS guidance [5].

4.4 IVUS MLA <6 mm² is Best Anatomical Parameter of LM Stenosis Significance that Correlates Functionally with FFR < 0.80

We propose in our study that a MLA of greater than 6 mm² is a safe and appropriate cutoff for which to defer LMCA revascularization.

The Best IVUS parameter that correlated best with hemodynamically significant of LM lesions as correlated with FFR measures was MLA <5.9 mm² (sensitivity, 93%; specificity, 95%). These are the figures used in EXCEL trial. In the LITRO study, prospective multicenter study including 354 patients, the 6 mm² cut-off value was clinically validated. [6].

In the case of LM disease Functional assessment can be substituted with anatomical imaging by IVUS, as there are different studies that have demonstrated a strong correlation between lumen area and functional significance of LM stenosis. An important advantage of IVUS compared with FFR for LMCA evaluation is the ability to obtain key morphologic information, such as characterization of the severity and extent of disease (eg. ostial LAD and/or ostial left circumflex involvement, plaque burden calcification that may require atherectomy) [9].

Jasti et al. in 2004 and Jacek Legutko et al 2012 showed that a MLA less than 5.9 mm² correlate with FFR <0.75 in LM coronary disease. In another prospective clinical trial applied on 354 patients, Dela Torre Hernandez et al, in 2011 showed that a MLA less than 6 mm² suggests a significant LMCA stenosis. [8].

In comparison with Asian population Kang SJ et al, 2011 and Park et al in 2014, concluded that in isolated LM disease, an IVUS-derived MLA <4.5 mm² in Park et al study and IVUS-derived MLA <4.8 mm² in Kang SJ et al are a useful criterion for predicting FFR <0.80, so in conclusion there is a narrow range for the left main (LM) coronary artery minimal lumen area (MLA) cutoff of about 6 mm². Incorporation of other factors is required to make an individualized, case-based decision. IVUS appears also useful in assessing lesions located in the left main coronary artery (LMCA). [7].

The meta-analysis shows that in patients with ambiguous LMCA disease, deferral of revascularization based on FFR results is safe in terms of overall mortality and subsequent

myocardial infarctions. In 2015 Mallidi J et al studied in prospective cohort studies involving 525 patients and concluded that the long term clinical outcomes in patients with ambiguous LMCA stenosis is for whom revascularization is deferred based on FFR are favorable and similar to the revascularized group (41%) with no statistically significant difference between the groups in the rates of primary end point (P=0.15), in terms of overall mortality and subsequent myocardial infarctions [11].

Single center data suggests that the impact of operator volume of LM cases gets better outcomes in LMCA with less benefit from IVUS guidance replicating some historical randomized trial data that didn't clearly support IVUS imaging in every case [12].

5. LIMITATION

This study has several limitations. First, it was a two-center study, the sample size was small. We could not perform a sub-group analysis to investigate whether diabetes or bifurcation lesions and techniques influence the beneficial results of IVUS. Second, pre-procedure and post procedure of LCX pullback were not checked in most single stent cases, so we did not gain IVUS imaging of LCX in these patients. Third, patients with low ejection fraction were excluded, comprising a large portion of ULMCA in the real world. In conclusion, IVUS use during ULMCA intervention may improve clinical outcomes. Forth: In our study, we compare short term clinical outcome over 6,18 months of follow up of both groups as regarding MACE, however in long term outcomes IVUS groups could have mortality benefits,

6. CONCLUSION

IVUS could improve the clinical outcome of coronary intervention through decreasing the incidence of MACE events particularly the incidence of target lesion revascularization; however, it has no clinical impact on mortality and myocardial infarction.

CONSENT AND ETHICAL APPROVAL

All patients were informed of the investigative nature of the study and gave written informed consent before enrollment. The study was approved by the ethics committee of the affiliated hospitals of Tanta university and San Donato.

COMPETING INTERESTS

Authors have declared that no competing interests exist.

REFERENCES

1. Park SJ, Kim YH, Park DW, Yun S-C, Ahn JM, Song HG, et al. Randomized Trial of Stents versus Bypass Surgery for Left Main Coronary Artery Disease. *N Engl J Med*. 2011;364(18):1718–27.
2. Nishimura RA, Edwards WD, Warnes CA, Reeder GS, Holmes DR, Tajik AJ, et al. Intravascular ultrasound imaging: in vitro validation and pathologic correlation. *J Am Coll Cardiol*. 1990 J;16(1):145–54.
3. Mintz GS, Lefèvre T, Lassen JF, Testa L, Pan M, Singh J, et al. Intravascular ultrasound in the evaluation and treatment of left main coronary artery disease: a consensus statement from the European Bifurcation Club. *EuroIntervention*. 2018;14(4):e467–74.
4. Buccheri S, Franchina G, Romano S, Puglisi S, Venuti G, D'Arrigo P, et al. Clinical Outcomes Following Intravascular Imaging-Guided Versus Coronary Angiography-Guided Percutaneous Coronary Intervention With Stent Implantation. *JACC Cardiovasc Interv*. 2017;10(24):2488–98.
5. Zhang J, Gao X, Kan J, Ge Z, Han L, Lu S, et al. Intravascular Ultrasound Versus Angiography-Guided Drug-Eluting Stent Implantation. *J Am Coll Cardiol*. 2018;72(24):3126–37.
6. Park SJ, Kim YH, Park DW, Lee SW, Kim WJ, Suh J, et al. Impact of Intravascular Ultrasound Guidance on Long-Term Mortality in Stenting for Unprotected Left Main Coronary Artery Stenosis. *Circ Cardiovasc Interv*. 2009;2(3):167–77.
7. Tan Q, Wang Q, Liu D, Zhang S, Zhang Y, Li Y. Intravascular ultrasound-guided unprotected left main coronary artery stenting in the elderly. *Saudi Med J*. 2015;36(5):549–53.
8. De la Torre Hernandez JM, Garcia Camarero T. Intravascular Ultrasound for the Diagnosis and Treatment of Left Main Coronary Artery Disease. *Interv Cardiol Clin*. 2015;4(3):361–81.
9. Kim YH, Her AY, Rha SW, Choi BG, Shim M, Choi SY, et al. Three-Year Major Clinical Outcomes of Angiography-Guided Single Stenting Technique in Non-Complex Left Main Coronary Artery Diseases. *Int Heart J*. 2017;58(5):704–13.
10. Fan ZG, Gao XF, Li XB, Shao MX, Gao YL, Chen SL, et al. The outcomes of intravascular ultrasound-guided drug-eluting stent implantation among patients with complex coronary lesions: a comprehensive meta-analysis of 15 clinical trials and 8,084 patients. *Anatol J Cardiol*. 2017;17(4):258–68.
11. Andell P, Karlsson S, Mohammad MA, Götberg M, James S, Jensen J, et al. Intravascular Ultrasound Guidance Is Associated With Better Outcome in Patients Undergoing Unprotected Left Main Coronary Artery Stenting Compared With Angiography Guidance Alone. *Circ Cardiovasc Interv*. 2017;10(5).
12. Xu B, Redfors B, Yang Y, Qiao S, Wu Y, Chen J, et al. Impact of Operator Experience and Volume on Outcomes After Left Main Coronary Artery Percutaneous Coronary Intervention. *JACC Cardiovasc Interv*. 2016;9(20):2086–93.

© 2020 Ezzelregal et al.; This is an Open Access article distributed under the terms of the Creative Commons Attribution License (<http://creativecommons.org/licenses/by/4.0>), which permits unrestricted use, distribution, and reproduction in any medium, provided the original work is properly cited.

Peer-review history:

The peer review history for this paper can be accessed here:
<http://www.sdiarticle4.com/review-history/59665>