



Emergence of Mucormycosis during COVID-19 Pandemic in India

**Bramhadev Pattnaik ^{a#}, Sharanagouda S. Patil ^b, Gayatri Vaidya ^c,
Mahendra P. Yadav ^d, Shashanka K. Prasad ^e, Chandan Dharmashekar ^e,
Bhargav Shreevatsa ^e, Chandrashekar Srinivasa ^f, Kollur Shiva Prasad ^g,
P. Ashwini ^h and Chandan Shivamallu ^{e*}**

^a Institute of Veterinary Science and Animal Husbandry, SoA University, Odisha, India and ICAR-DFMD, Mukteswar, Nainital, India and FAO Ref Centre for FMD in South Asia, Bhubaneswar, Odisha, India.

^b ICAR-National Institute of Veterinary Epidemiology and Disease Informatics (NIVEDI), Yelahanka, Bengaluru, India.

^c Department of Studies in Food Technology, Davangere University, Davangere, Karnataka- 577007, India.

^d SVP University of Agriculture & Technology, Meerut, India.

^e Department of Biotechnology and Bioinformatics, School of Life Sciences, JSS Academy of Higher Education and Research, Mysuru, Karnataka- 570015, India.

^f Department of Studies in Biotechnology, Davangere University, Shivagangotri, Davangere, Karnataka-577 007, India.

^g Department of Sciences, Amrita School of Arts and Sciences, Amrita Vishwa Vidyapeetham, Mysuru Campus, Mysuru, Karnataka- 570026, India.

^h Department of Microbiology, School of Life Sciences, JSS Academy of Higher Education and Research, Mysuru, Karnataka- 570015, India.

Authors' contributions

This work was carried out in collaboration among all authors. All authors read and approved the final manuscript.

Article Information

DOI: 10.9734/JPRI/2021/v33i50B33432

Editor(s):

- (1) Dr. Rafik Karaman, Al-Quds University, Palestine.
- (2) Dr. Giuseppe Murdaca, University of Genoa, Italy.
- (3) Dr. Sung-Kun Kim, Northeastern State University, USA.

Reviewers:

- (1) Dzulsuhaimi Daud, Universiti Teknologi Mara, Malaysia.
- (2) Sachin Balkrishna Somwanshi, PRES's, College of Pharmacy (For Women), India.
- (3) Jesús G. Rodríguez Diego, Universidad Autónoma Metropolitana, (UAM), Unidad Xochimilco, México.
- (4) Sónia Ferreira, University of Aveiro, Portugal.

Complete Peer review History: <https://www.sdiarticle4.com/review-history/76244>

Review Article

Received 28 September 2021

Accepted 28 October 2021

Published 18 November 2021

[#]Former Director

^{*}Corresponding author: E-mail: chandans@jssuni.edu.in;

ABSTRACT

The present review describes about the disease and the fungal agent in brief, and also stresses for establishment of mechanically ventilated hospital wards across the country. Second wave of COVID-19 pandemic in India has been complicated by high infection rate (R_0), 600% jump in medical oxygen demand by COVID hospitals, and after all emergence of Mucormycosis since April-May 2021 leading to fatal complications. Mucormycosis is a very rare infection in humans. It is caused by exposure to mucor mould/ fungi which is commonly found in soil, plants, manure, and decaying fruits and vegetables. These Fungi belonging to the class Zygomycetes and order Mucorales often cause devastating angio-invasive infections, primarily in co-morbid and immunocompromised patients. The emergence of mucormycosis is being reported globally. In India, people with diabetes mellitus are highly susceptible to the disease. But during the second wave of Covid-19 in India, several cases of mucormycosis, also called the "black fungus" disease, have been reported among convalescing and convalescent COVID-19 patients across India with a mortality rate of 50%. More than 5000 cases of mucormycosis during the second wave of Covid-19, have been reported in about 21 states of the country, with Maharashtra and Gujarat states reporting highest number of cases (as on 21 May 2021). The infection has claimed over 120 lives so far, and has complicated recovery from Covid-19 in many more. The Indian Union health ministry has declared mucormycosis as a notified disease under the Epidemic Diseases Act, 1897.

Keywords: COVID-19; diagnosis and treatment; epidemic disease; India; mucormycosis.

1. INTRODUCTION

Most fungi are saprophytic and not pathogenic to humans, animals and plants. Fungi members of the genera *Aspergillus*, *Fusarium*, *Alternaria*, and *Mucor* are emerging pathogen in humans mostly in immunocompromised people. Mucormycosis is an emerging opportunistic fungal infection/disease, caused by Mucoromycetes of the order Mucorales, in people with risk factors, such as immunosuppression, diabetes, trauma and malignancies [1], and of late associated with second wave of COVID-19 in India. In a prospective multicenter study, Mucormycosis is reported at large numbers in uncontrolled diabetics across India [2]. Trauma was the other main cause. *Rhizopus arrhizus* (51.9%) was the predominant Mucorale/ agent identified, followed by *Rhizopus microsporus* (12.6%), *Apophysomyces variabilis* (9.2%) and *Rhizopus homothallicus* (2.5%). Several new species have also been identified to cause mucormycosis in India including *Rhizopus homothallicus*, *Thamnostylum lucknowense* and *Mucor irregularis*. Fungal infections of the central nervous system (CNS) are on progressive rise in humans (Goralska et al., 2018). They have described causative fungal agents as Mucoromycetes (*Mucor* and *Rhizopus* species), dimorphic fungi (*Blastomyces dermatitidis*, *Histoplasma capsulatum* and *Coccidioides* species), dematiaceous fungi (*Cladophialophora bantiana*, *Exophiala dermatitidis*), Yeasts (*Cryptococcus*, *Candida* and *Trichosporon*

species), and Moniliaceous fungi (*Aspergillus* and *Fusarium* species). Both Mucoromycetes and Moniliaceous fungi are filamentous; the former has non-septate hyphae, whereas the latter have septate hyphae. Yeasts are unicellular organisms. The dimorphic fungi have two morphological stages; mold/ mould in environment and yeast in tissue. Pigmented moulds with neurotropism, like *Cladophialophora bantiana*, *Exophiala dermatitidis*, *Verruconis/Ochroconis gallopava* and *Rhinocladiella mackenziei* have been described in different parts of the World. The increasing number of infections by Mucorales with high mortality is a serious public health issue [3]. *Mucor circinelloides* is one of the most frequent species causing fatal mucormycosis. Mucorales infections are difficult to treat due to fast dissemination within the host tissues and low susceptibility to antifungal agents, and may lead to aspergillosis. They observed that phenotypical characteristics related to virulence include higher germination rate, spore size and protein secretion. Mucormycosis remains a major fungal infection in people with diabetes (Prasad et al., 2018). Therefore, an insight in to overall picture of Mucormycosis and its causative agents are discussed in this review.

2. NATURE OF FUNGI

Fungi are eukaryotes that include microorganisms such as yeasts, moulds, and

mushrooms, and are classified as a kingdom separate from the other eukaryotic kingdoms of Plantae, Animalia, Protozoa, and Chromista [4]. The fungi are unique in having chitin in the cell wall, and have different morphologies and varied replication strategy. The Kingdom Fungi, has been estimated to have more than 2 million species; >8,000 species known to be pathogenic to plants and about 300 that can be pathogenic to humans. As in other eukaryotes, fungal cells contain nuclei with chromosomes that contain DNA with introns and exons, mitochondria, and ribosomes. Fungi typically have haploid nuclei. As in plants, fungi have cell wall but lack chloroplast (no photosynthesis). Fungi, like animals, are heterotrophs; and secrete digestive enzymes into their environment.

3. MUCORMYCOSIS

Mucormycosis/ zygomycosis remains a devastating invasive fungal infection with high mortality rates and is being reported over the past decades from India [5]. Mucormycosis in India has unique features as rhino-orbito-cerebral disease in people with uncontrolled diabetes. Also, renal mucormycosis has been diagnosed. *Apophysomyces elegans*, *Rhizopus thallicus*, *Mucor irregularis* and *Thamnostylum lucknowense* have been

identified in India. The mucor fungi (Fig. 1) have garnered enough attention, owing to the occurrence of mucormycosis in COVID-19 patients across India. Mucormycosis classified as follows [6,7].

1. *Rhinocerebral mucormycosis* – It is also known as the rhino-orbital or rhino-orbito-cerebral mucormycosis that involve sinuses and brain in people with diabetes and/or renal complications [8,9,10].
2. Pulmonary mucormycosis– It is detected in people suffering from hematologic malignancy or following organ/ stem cell transplant [11].
3. Gastrointestinal mucormycosis– It commonly occurs in children, with premature birth or low birth weight, and also due to antibiotics/immunosuppressant, and surgery [12].
4. Cutaneous mucormycosis– It commonly occurs due to entry of the fungi through breaks/ abrasions in the cutaneous/skin tissues [13].
5. Disseminated mucormycosis– It commonly affects the vital organs, such as brain, heart, spleen, kidney and skin, upon spread of the fungus through the bloodstream [14].

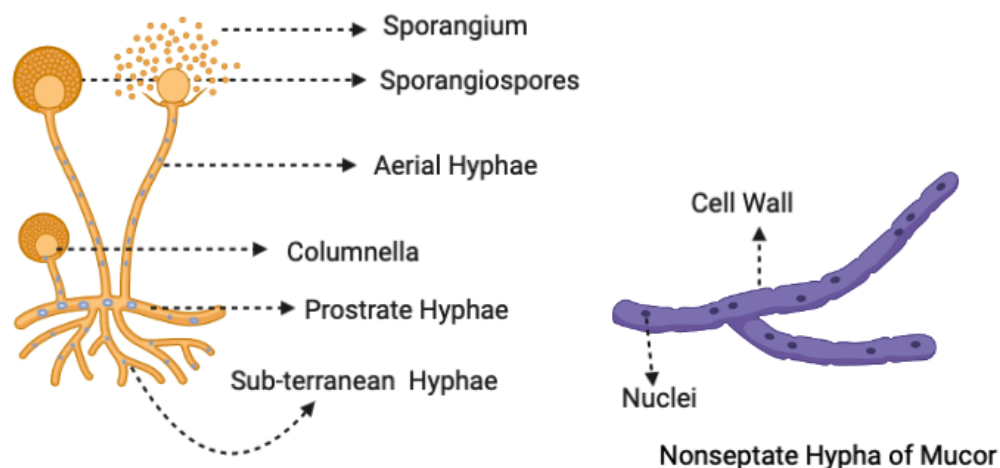


Fig. 1. Structure of the Mucor (Created with BioRender.com) [Kingdom: Mycota, Division: Zygomycota, Sub-division: Zygomycotina, Class: Zygomycetes, Order: Mucorales, Family: Mucoraceae, Genus: Mucor]

3.1 The Agent

Mucormycosis is caused by fungi belonging to the phylum *Mucormycota* and order *Mucorales*, which grow in all kinds of moist, decaying organic matter in the environment. As many as 261 species diversified into 55 genera comprise the order *Mucorales*, of which nearly 38 species have been reported to be infectious to humans. The thermo tolerant nature of these organisms empower them to grow at the human body temperature (Roden *et al.*, 2005). *Mucor* (18%), *Rhizopus* (47%), *Cokeromyces* (3%), *Cunninghamella* (7%), *Lichtheimia* (5%), *Rhizomucor* (4%), *Apophysomyces* (5%), *Syncephalastrum* (3%), *Saksenaea* (5%), *Thamnostylum* (3%) species have been regarded the most common causal agents of mucormycosis. The mucor fungi comprise of a well-developed thallus and branched mycelium freely exposed to air. Reproduction can be vegetative, asexual or sexual. Fragmentation of mycelium results in the vegetative proliferation of fresh mycelia. Asexual reproduction in *Mucorales* occurs through the non-motile sporangiospores etc. Sexual reproduction in the black fungus is isogamous, occurring by the means of gametangial copulation [15].

3.2 Mode of Transmission

Common route of transmission is inhalation or inoculation through trauma or surgery, with subsequent haematogenous or contiguous spread. Mucormycosis exhibits in a variety of human organs including rhino-orbital-cerebral, pulmonary, gastrointestinal, cutaneous, as well as disseminated disease. Pulmonary mucormycosis is the second most common presentation (after Rhinocerebral), representing up to 58% of infections [16], and is known for its aggressive clinical course with a mortality rate of up to 80% [17,18].

3.3 The Disease and Symptoms

Based on the site of infection, the cases of mucor mycosis were categorized as Rhino-orbito-cerebral (63.9%), pulmonary (12.9%), cutaneous (9.5%), gastro intestinal (6.4%), renal (5.4%), and others [18]. The clinical symptoms and signs first appear usually in the infected body area, accompanied with fever, headache, reddish and swollen skin over nose and sinuses, dark scabs in nose, swelling of eye and problem in vision, facial pain, coughing with dark

exudate, shortness of breath, abdominal pain etc.

3.4 Diagnosis

Sometimes diagnosis becomes very difficult due to non-specific symptoms. Early diagnosis of fungal infection along with the identification of the causative fungi, is needed for effective therapy. Early diagnosis of mucormycosis in humans remains elusive due to difficulty in sample collection from deep tissues and absence of a biomarker [19]. The isolation of *Mucorales* fails in considerable number of cases due to the delicate nature of the hyphae. The cases of mucormycosis can be diagnosed by histopathological and mycological techniques. Ribosomal DNA is targeted for precise diagnosis [20].

3.5 Treatment

Pharmaceutical formulations of amphotericin B (AmB), usually liposomal AmB (lAmB) has been used to treat mucormycosis, cryptococcal meningoencephalitis, and Candidiasis of CNS. Flucytosine, and triazoles like Voriconazole, Posaconazole, Itraconazole, Isavuconazole have been used in therapy of different fungal infections of CNS and other vital organs. Patients managed with a combination of surgical debridement and AmB therapy had significantly lower mortality [21]. AmB, posaconazole, and deferasirox are used to treat mucormycosis patients in India.

4. CONCLUSION

Co-morbidity and also immunosuppression can make commensals/ saprophytes opportunistic pathogens. Mucormycosis is one such condition. *Mucorales* are pathogenic to both plants and humans. The India saw increasing instances of COVID-19-associated mucormycosis (CAM), a systemic fungal infection caused by the *Mucorales* species. The epidemiology of mucormycosis in India is different from European countries and the United States. Diabetes mellitus is the predominant risk factor in India but during the second wave of COVID-19, emergence and spread of mucormycosis since April-May 2021 has become a threat to the Covid-19 control program in India. This has been a threat to the critical care Covid-19 patients, and also convalescent ones. Due to aerosol transmission of fungal spores/ hyphae, necessity of additional safety requirements has

further stressed the national COVID task force and the health system. To learn a lesson from Covid-19- Mucormycosis complex, it would be apt to plan for establishment of mechanically ventilated (100% exhaust/ fresh air) hospital wards as a routine across the country. In order to take preventive measures, COVID-19 protocols like wearing of mask, maintaining physical distance, washing of hands with soap and use of sanitizers would be of more handy.

DISCLAIMER

The products used for this research are commonly and predominantly use products in our area of research and country. There is absolutely no conflict of interest between the authors and producers of the products because we do not intend to use these products as an avenue for any litigation but for the advancement of knowledge. Also, the research was not funded by the producing company rather it was funded by personal efforts of the authors.

CONSENT

It is not applicable.

ETHICAL APPROVAL

It is not applicable.

COMPETING INTERESTS

Authors have declared that no competing interests exist.

REFERENCES

1. Khera S, Singh V, Pattanayak S. Favourable outcome in a child with acute lymphoblastic leukaemia and pulmonary mucormycosis managed with combination antifungal therapy of liposomal amphotericin B and caspofungin. *BMJ Case Reports*. 2021;14(10): e245329.
2. Prakash H, Ghosh AK, Rudramurthy SM, Singh P, Xess I, Savio J, Pamidimukkala U, Jillwin J, Varma S, Das A, Panda NK, Singh S, Bal, A. A prospective multicenter study on mucormycosis in India: Epidemiology, diagnosis, and treatment. *Medical Mycology*. 2018;57(4): 395-402.
3. Prakash H, Chakrabarti A. Epidemiology of mucormycosis in India. *Microorganisms*. 2021;9(3):523
4. Hawksworth, DL, Lücking R. Fungal diversity revisited: 2.2 to 3.8 million species. *Microbiology Spectrum*. 2017;5(4). Available: <https://doi.org/10.1128/microbiolspec.FUNK0052-2016>.
5. Chakraborti A, Singh R. Mucormycosis in India: unique features. *Mycoses*. 2014;57(3):1-6.
6. Petrikos G, Skiada A, Lortholary O, Roilides E, Walsh TJ, Kontoyiannis DP. Epidemiology and clinical manifestations of mucormycosis. *Clinical Infectious Diseases*. 2012;54(1):S23-34.
7. Ribes JA, Vanover-Sams CL, Baker DJ. Zygomycetes in human disease. *Clinical Microbiology Reviews*. 2000;13:236-301.
8. Song Y, Qiao J, Giovanni G, Liu G, Yang H, Wu J, Chen J. Mucormycosis in renal transplant recipients: review of 174 reported cases. *BMC Infectious Diseases*. 2017;17(1): 283.
9. Abdalla A, Adelman D, Fahal A, Verbrugh H, Van Belkum A, De Hoog S. Environmental occurrence of *Madurellamycetomatis*, the major agent of human eumycetomic in Sudan. *Journal of Clinical Microbiology*. 2002;40(3):1031–1036.
10. Deek AJ, Boukovalas S, Rathfoot CJ, Gotcher JE. Rhinocerebral Mucormycosis as a Sequelae of COVID-19 Treatment: A Case Report & Literature Review. *J Oral Maxillofac Surg*. 2021;S0278-2391(21):01119-8.
11. Agrawal R, Yeldandi A, Savas H, Parekh ND, Lombardi PJ, Hart EM. Pulmonary Mucormycosis: Risk Factors, Radiologic Findings, and Pathologic Correlation. *Radiographics*. 2020;40(3):656-666.
12. Francis JR, Villanueva P, Bryant P, Blyth CC. Mucormycosis in children: review and recommendations for management. *Journal of Paediatrics Infectious Diseases Society*. 2018;7(2):159-164.
13. Celgow L, Cohn RJ, Sacks AJ. Disseminated mucormycosis: report of a successfully treated immunosuppressed child with clinical, radiographic and pathological findings. *Pediatric Radiology*. 1996;26(2):131-3.

14. Morin-Sardin S, Node P, Coton E, Jany J-L, Mucor. A Janus-faced fungal genus with human health impact and industrial applications. *Fungal Biology Reviews*. 2017;31(1):12–32.
15. Dube HC. *Fungi, general characteristics. An introduction to fungi*, 2nd revised edn. Vikas, New Delhi. 1990;11–146.
16. Danion F, Aguilar C, Catherinot E, Alanio A, DeWolf S, Lortholary O, Lanternier F. Mucormycosis: new developments into a persistently devastating infection. *Semin Respir Crit Care Med*. 2015;36(5):692–705.
17. Tedder M, Spratt JA, Anstadt MP, Hegde SS, Tedder SD, Lowe JE. Pulmonary mucormycosis: results of medical and surgical therapy. *Ann Thorac Surg*. 1994;57(4):1044–50.
18. López-Fernández L, Sanchis M, Navarro-Rodríguez PE, Nicolás FE, Silva-Franco F, Guarro J, Garre V, Navarro-Mendoza MI, Pérez-Arques C, Capilla J. Understanding *Mucor circinelloides* pathogenesis by comparative genomics and phenotypical studies. *Virulence*. 2018;9(1):707-720.
19. Góralaska K, Blaszkowska J, Dzikowiec M. Neuroinfections caused by fungi *Infection*. 2018;46:443–459.
20. Richardson M. The ecology of the Zygomycetes and its impact on environmental exposure. *Clin Microbiol Infect*. 2009;15(10):Suppl 5:2-9
21. Roden MM, Zaoutis TE, Buchanan WL, Knudsen TA, Sarkisova TA, Schaufele RL. Epidemiology and outcome of zygomycosis: a review of 929 reported cases. *Clinical Infectious Diseases*. 2005;41(5):634-53.

© 2021 Pattnaik et al.; This is an Open Access article distributed under the terms of the Creative Commons Attribution License (<http://creativecommons.org/licenses/by/4.0>), which permits unrestricted use, distribution, and reproduction in any medium, provided the original work is properly cited.

Peer-review history:
The peer review history for this paper can be accessed here:
<https://www.sdiarticle4.com/review-history/76244>