

## 3-year results of transvaginal cystocele repair with transobturator four-arm mesh: A prospective study of 105 patients

Moez Kdous & Fethi Zhioua

To cite this article: Moez Kdous & Fethi Zhioua (2014) 3-year results of transvaginal cystocele repair with transobturator four-arm mesh: A prospective study of 105 patients, Arab Journal of Urology, 12:4, 275-284, DOI: [10.1016/j.aju.2014.09.007](https://doi.org/10.1016/j.aju.2014.09.007)

To link to this article: <https://doi.org/10.1016/j.aju.2014.09.007>



© 2014 Arab Association of Urology



Published online: 05 Apr 2019.



Submit your article to this journal [↗](#)




Article views: 366



View related articles [↗](#)



View Crossmark data [↗](#)



ORIGINAL ARTICLE

# 3-year results of transvaginal cystocele repair with transobturator four-arm mesh: A prospective study of 105 patients



Moez Kdous \*, Fethi Zhioua

Department of Obstetrics and Gynecology, Aziza Othmana Hospital, Tunis, Tunisia

Received 27 January 2014, Received in revised form 1 May 2014, Accepted 24 September 2014  
Available online 11 November 2014

## KEYWORDS

Genital prolapse;  
Cystocele;  
Transvaginal mesh;  
Polypropylene mesh

## ABBREVIATIONS

VAS, visual analogue scale;  
TOT, transobturator tape;  
TVT, tension-free vaginal tape;  
TAPF, tendinous arch of the pelvic fascia;  
SUI, stress urinary incontinence;  
QoL, quality of life;

**Abstract Objectives:** To evaluate the long-term efficacy and safety of transobturator four-arm mesh for treating cystoceles.

**Patients and methods:** In this prospective study, 105 patients had a cystocele corrected between January 2004 and December 2008. All patients had a symptomatic cystocele of stage  $\geq 2$  according to the Baden–Walker halfway stratification. We used only the transobturator four-arm mesh kit (Surgimesh®, Aspide Medical, France). All surgical procedures were carried out by the same experienced surgeon. The patients' characteristics and surgical variables were recorded prospectively. The anatomical outcome, as measured by a physical examination and postoperative stratification of prolapse, and functional outcome, as assessed by a questionnaire derived from the French equivalents of the Pelvic Floor Distress Inventory, Pelvic Floor Impact Questionnaire and the Pelvic Organ Prolapse–Urinary Incontinence–Sexual Questionnaire, were considered as the primary outcome measures. Peri- and postoperative complications constituted the secondary outcome measures.

**Results:** At 36 months after surgery the anatomical success rate (stage 0 or 1) was 93%. On a functional level, all the scores of quality of life and sexuality were improved. The overall satisfaction score (visual analogue scale) was 71.4%. There

\* Corresponding author at: Department of Obstetrics and Gynecology, Aziza Othmana Hospital, 1008 Tunis, Tunisia. Tel.: +216 21 852683 (mobile); fax: +216 71 849136.

E-mail address: moezkdous@yahoo.fr (M. Kdous).

Peer review under responsibility of Arab Association of Urology.



Production and hosting by Elsevier

PFDI, Pelvic Floor Distress Inventory; PPISQ-12, Pelvic Organ Prolapse/Urinary Incontinence-Sexual Questionnaire; PFDIQ, Pelvic Floor Distress Impact Questionnaire

were no perioperative adverse events. Mesh erosion was reported in 7.6% and mesh retraction in 5.7% of the patients.

**Conclusions:** If the guidelines and precautions are followed, vaginal prosthetic surgery for genitourinary prolapse has shown long-term benefits. It provides excellent results both anatomically and functionally. However, complications are not negligible and some are specific to prosthetic surgery.

© 2014 Production and hosting by Elsevier B.V. on behalf of Arab Association of Urology. This is an open access article under the CC BY-NC-ND license (<http://creativecommons.org/licenses/by-nc-nd/3.0/>).

## Introduction

Anterior genital prolapse or cystocele is a relaxation in the anterior vaginal wall, as described by De Lancey and Richardson [1]. Central and lateral cystoceles are distinguished according to the anatomical mechanism of connective tissue damage [2]. Lateral cystoceles are secondary to damage of the vaginal hammock fasteners to the pelvic wall at the level of the tendinous arch of the pelvic fascia (TAPF), whereas central cystoceles are secondary to the loss of support in the midline by Halban's fascia [3]. The repair of anterior genital prolapse, whether or not associated with stress urinary incontinence (SUI), remains the weak point of vaginal surgery, with recurrence rates of 30–50% depending on the technical methods and reporting authors [4].

Formerly managed by simple subvesical plication or anterior colporrhaphy, more than a third of cystoceles recur. Indeed, the traditional colporrhaphy only corrects the central defects, and furthermore, adds a suture under tension to the poor quality of native tissues. These disadvantages have led to the development of more reliable and durable surgical techniques, resulting in the use of various types of mesh in vaginal prolapse surgery. These materials act as a frame, guiding the development of stronger supporting tissue [5,6]. Lightweight macroporous polypropylene meshes are currently the reference material, and are marketed in the form of sheets or pre-cut kits.

The objective of the present study was to evaluate the long-term safety and efficacy of cystocele treatment using a transobturator four-arm polypropylene mesh.

## Patients and methods

In a prospective study at the authors' institution patients who had a clinical diagnosis of cystocele and who underwent prosthetic surgery using a transobturator four-arm mesh were enrolled between 1 January 2004 and 31 December 2008. Informed consent was obtained from all patients and approval was obtained from the Ethics Committee of the hospital before the first surgical procedure.

All patients were questioned about their gynaecological, obstetric, surgical and pelvi-perineal history. The

clinical examination aimed to reproduce the maximum degree of the anatomic prolapse, comprising a static part (gaping vulva, spontaneous exteriorisation of organs), and a dynamic part (externalisation during the Valsalva manoeuvre, or examination of SUI by coughing). Perineal testing and evaluation of the anal sphincter were systematic. Bonney or Ulmsten manoeuvres completed the examination if there was SUI.

Patients were included if they were aged > 50 years; had a cystocele of  $\geq$  grade II according to the classification of Baden and Walker [7], either isolated or associated with prolapse of the other stages, either initial or recurrent; functional discomfort warranting surgery; and the consent of the patient.

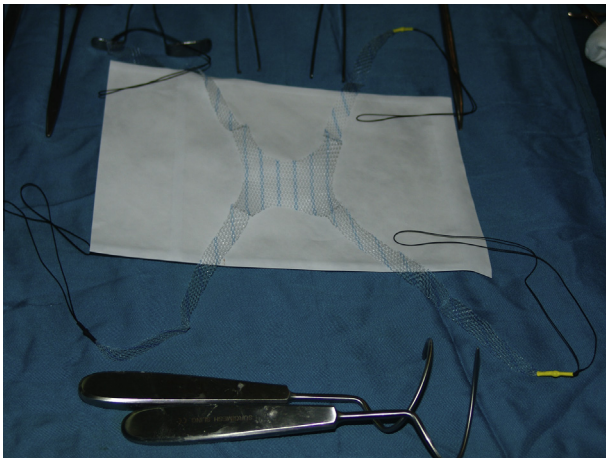
Patients were excluded if they had a medical contraindication against the intervention, a urinary or genital recurrent infection, a history of pelvic irradiation or of malignant neoplasm of the lower urinary tract, long-term corticosteroid therapy or other immune deficiency, adnexal mass, neurological disorder affecting the stability of the bladder (multiple sclerosis, spinal cord injury), or an indication for laparotomy for other causes.

## Procedure

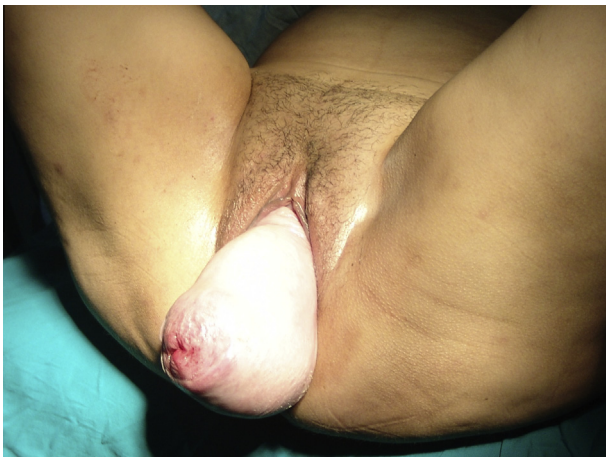Before surgery a urine sample was cultured, the pelvic area shaved and a cleansing enema given in all patients. We used the Surgimesh® prolapse kit (Aspide Medical, France) containing a macroporous monofilament polypropylene mesh of density 27.5 g/m<sup>2</sup>, and a set of transobturator tape (TOT) coil-type needles. The mesh is formed by a central portion shaped as a square of 5 cm<sup>2</sup> and four lateral arms of 12 cm each. The width of these arms is reduced gradually to reach 5 mm at the ends (Fig. 1).

## Technique

Spinal anaesthesia was preferred to general anaesthesia. Intravenous antibiotic prophylaxis (2 g cefazolin or amoxicillin/clavulanate) was routinely administered. The patient is placed in the dorsal lithotomy position, the buttocks slightly overlapping the table, and the thighs and legs in flexion. A large disinfection with povidone-iodine (or other non-iodised antiseptic in case of



**Figure 1** The polypropylene mesh, with a central part of 4–5 cm and four lateral wings of 12–13 cm long and 1 cm width. In front, the two needles used to make the tract for the mesh.



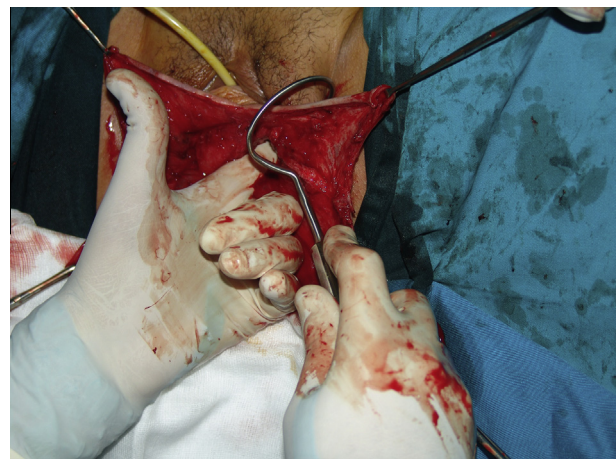**Figure 2** The patient is placed in the dorsal lithotomy position, buttocks slightly overlapping the table, thighs and legs in flexion. Preoperative aspect, stage IV prolapse.

allergy) was used, and a permanent urinary catheter was placed (Fig. 2).

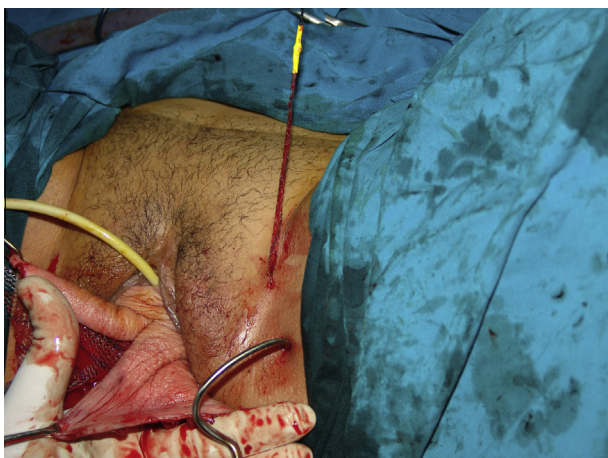The anterior vaginal wall is exposed by traction on the cervix or on the vaginal cuff if there was a previous hysterectomy. The procedure began with infiltration of the vaginal wall with a solution of lidocaine 1% with adrenaline to help with the dissection plane and reduce bleeding. A vertical midline incision of the anterior vaginal wall is made from  $\approx 2$  cm below the urethral meatus to the cervix (or vaginal cuff if there was a previous hysterectomy). In cases of associated hysterectomy, a median colpotomy connected in a T-shape to the transverse colpotomy of the hysterectomy is then made. Apically and in the midline, the bladder is dissected all the way up and off the cuff of the vagina or the cervix if the uterus was in place. This dissection should repulse the bladder gradually. The fascia of Halban is held against the vaginal wall, leaving sufficiently thick tissue to cover

the mesh after colporrhaphy. Laterally, the dissection is continued as far as possible, reaching the TAPF. This permits a large central and lateral exposure of the cystocele. In the space thus released, the implant is inserted between the vagina and bladder.

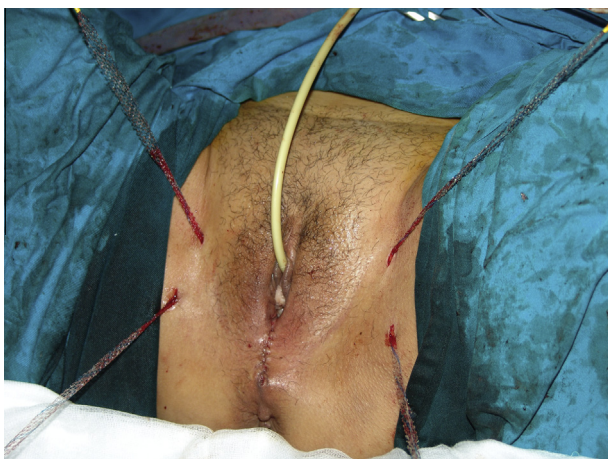The transobturator phase begins with the preparation of the surgical path by inserting the tip of Mayo scissors (which is concave outward) between the puborectalis muscle and the ischiopubic branch, the relief of which is marked by bone contact with the scissors tip. A deep layer of triangular ligament is opened with a firm movement that provides access to the anterior extension of the ischio-rectal space. The scissors are then opened and removed. Two skin incisions of 3 mm are made in the genito-femoral crease at the approximate level of the clitoral hood. The transobturator passage is tracked by palpation between the thumb and forefinger of the obturator membrane in contact with the ischio-pubic symphysis. The needle is introduced inwards, and punched through the obturator membrane, causing a marked 'jump'. It must then bypass the ischio-pubic branch, and be brought with direct finger guidance, at the level of the proximal part of the TAFP (Fig. 3). The mesh arms are then attached to the needles and then retracted from the groin incisions. A second pair of incisions is then made 3 cm inferior and 2 cm lateral to the superior incisions bilaterally. The needles are equipped in the same way as before, and are always introduced inwards. The needle is directed vertically, under finger guidance, to move behind the internal obturator muscle and emerge below the TAPF near its distal insertion, 1–2 cm distal to the ischial spine apically (Fig. 4). The vaginal finger is used to apply pressure on the levator aponeurosis so that the needle can transfix it. The mesh arms are then attached to the needles and are retracted



**Figure 3** The needle is introduced after a skin incision is made in the genito-crural line at the level of the urinary meatus, controlled by surgeon, below the ischiopubic ramus, punching it through the obturator membrane and externalising it through the vaginal incision (left side).



**Figure 4** A second incision is made 3 cm inferior and 2 cm lateral to the superior incision. The needle is equipped in the same way as before, and is introduced inwards under finger guidance (left side).



**Figure 5** The final aspect before the mesh arm section.

from the incisions. The implant must cover the entire dissected area. The arms are then adjusted and tightened in a tension-free fashion, considering the postoperative retraction of adjacent tissues. The prosthesis is fixed at two points with non-absorbable sutures placed in the pubic insertion of the levator. The portion of the vaginal section is closed by a running polyglactin 1/0 suture with no colectomy. The procedure is completed by the mesh arms section (Fig. 5).

After surgery patients received systematic paracetamol (1 g every 6 h). If needed, it was associated with either NSAIDs (ketoprofen 100 mg every 8 h) or, in case of persistent pain, with morphine sulphate. The bladder catheter and vaginal packing were retained for 48 h. If stable, patients were discharged home 4 days after surgery. All patients received antibiotic treatment for 5 days, laxatives for 15 days, and vaginal antiseptics daily for a month. Anticoagulant therapy was given

for 3 weeks from the date of surgery. Recommendations for local hygiene and sexual activity were given to patients systematically.

#### *Evaluation of results*

For the anatomical results, all patients had a clinical assessment before surgery according to the Baden and Walker stratification of prolapse [7], and all were re-examined at 4 weeks, 3 and 6 months, and then once a year after surgery. Only patients with stage 0 or 1 prolapse were considered as cured (stage I postoperative cystoceles were considered as physiological).

For the functional results, all patients completed self-administered questionnaires before and after surgery to assess symptoms, quality of life (QoL) and sexuality. This was repeated each time they were re-examined at the follow-up visits. The questionnaires used were the French equivalents of the Pelvic Floor Distress Inventory (PFDI), Pelvic Floor Distress Impact Questionnaire (PFIQ) and the Pelvic Organ Prolapse–Urinary Incontinence–Sexual Questionnaire (PISQ-12) [8,9]. All patients had a systematic preoperative multichannel urodynamic assessment with reduction of the prolapse, according to the ICS standard [10].

When preoperative symptoms were associated with the four most common clinical variables (vaginal globus, pelvic heaviness, dyspareunia and urinary symptoms), the results of surgery were considered as ‘excellent’, if none of these symptoms were reported after surgery, as ‘good’ when any of the symptoms persisted, as ‘medium’ when two symptoms persisted, ‘poor’ when three symptoms persisted, and ‘bad’ when all four remained unchanged. An excellent or good result was considered as ‘success’.

Subjective outcomes were also assessed using a visual analogue scale (VAS, 0–10 on a horizontal ruler, with 0 = ‘very disappointed’ to 10 ‘very satisfied’). Patients responded to the question ‘How do you rate the results of the surgery?’, thus determining a score for overall satisfaction of 0–10.

#### *Complications*

We evaluated intraoperative (occurring during surgery), early and late complications. Early complications were defined as those that developed within 30 days after surgery and late as those observed  $\geq 30$  days after surgery. Clinical data were analysed using the chi-squared test or Fisher’s exact test when appropriate for qualitative variables, and Student’s *t* and Wilcoxon tests for quantitative variables, with  $P < 0.05$  considered to indicate statistical significance.

#### **Results**

In all, 105 women were included in the study, and their baseline demographic and clinical variables are shown in Table 1. The four most common preoperative symptoms

**Table 1** The baseline demographic and clinical variables of the 105 patients.

Variable	Mean (SD, range) or n (%)
Age (years)	63.4 (4.2, 52–73)
Parity	3.2 (1.2, 1–8)
Body mass index (kg/m <sup>2</sup> )	25.2 (4, 18.1–35.9)
Postmenopausal women	103 (98)
Sexually active <sup>a</sup>	82 (78)
Previous hysterectomy	18 (17)
Previous three compartment prolapse repair	16 (15)
Abdominal route	4 (4)
Vaginal route	12 (11)
Previous:	
Anterior vaginal wall repair only	4 (4)
Posterior colporrhaphy only	7 (7)
Anterior + posterior repair	2 (2)
SUI procedure	7 (7)
Burch colposuspension	4 (4)
TVT	3 (3)

<sup>a</sup> At least one sexual intercourse per month.

**Table 2** Subjective prolapse symptoms, as n (%), before and after surgery in the 105 patients.

Symptom	Before	36 months after	P
Chronic pelvic pain	12 (11)	3 (3)	<0.05
Pelvic heaviness	99 (94)	12 (11)	<0.05
Vaginal globus	105 (100)	4 (4)	<0.05
Urinary symptoms	86 (82)	18 (17)	<0.05
Urgency	37 (35)	12 (11)	<0.05
SUI	29 (28)	2 (2)	<0.05
		(+2 de novo)	
Dysuria	20 (19)	2 (2)	<0.05
Sexually active <sup>a</sup>	82 (78)	74 (70)	NS
With sexual intercourse:			
Pain	28 (27)	5 (5)	<0.05
Discomfort	39 (37)	2 (2)	<0.05
Dyspareunia	71 (68)	12 (11)	<0.05
		(+2 de novo)	
Difficulties in rectal voiding	2 (2)	0	<0.05
Anal incontinence	2 (2)	2 (2)	NS
Constipation	35 (33)	28 (27)	NS
Dyschesia	9 (9)	5 (5)	NS
All four <sup>b</sup>	85 (81)	4 (4)	<0.05

NS, not significant.

<sup>a</sup> With at least one sexual intercourse/month.

<sup>b</sup> Pelvic heaviness, vaginal globus, urinary symptoms, dyspareunia.

reported were vaginal globus, found in all patients, pelvic heaviness in 99 (94%), dyspareunia in 91 (87%) and urinary symptoms in 86 (82%). These four signs were associated in 85 patients (81%) (Table 2). The correlations between urinary symptoms before surgery and the urodynamic assessment are shown in Table 3.

All patients had  $\geq$ stage II cystocele according to the Baden and Walker stratification (Table 3). When

prosthetic transvaginal cystocele repair was used alone the duration of surgery was  $27 \pm 2.3$  min (ranges: 25–45 min). We performed 197 concomitant procedures, including 67 hysterectomies, 10 sacro-spinofixations (Richter procedure), 12 rectocele repairs by interposing a polypropylene prosthesis in the rectovaginal space and 14 by simple pre-rectus fascia plication, 75 perineal plasties associated with posterior levator myorrhaphy, and 19 treatments of SUI (according to clinical and urodynamic exploration) using a tension-free TOT. Patients underwent TOT as a concomitant procedure only when a physical assessment, objective SUI and urodynamic assessment showed urethral hypermobility or sphincter deficiency only. For all other cases (mixed urinary incontinence, bladder hypocontractility, etc.) the management of the urinary incontinence differed after cystocele repair. Suburethral tape was inserted in the same operative time at the end of the cystocele repair procedure, through a distinct vaginal incision, to avoid the risk of its displacement.

The intervention was feasible in all patients, and there were no intraoperative complications, e.g., haemorrhage or organ injury. The mean (SD) postoperative stay was 5 (2.2) days. Antibiotic prophylaxis and heparin therapy were instituted in all patients. The immediate and early postoperative adverse events are shown in Table 4. There were no postoperative haemorrhages or haematoma. Seven patients had fever on the first day after surgery that regressed spontaneously within 48–72 h, and six had transitory urinary retention. One patient had a postoperative levator myalgia that required short-term treatment with a muscle relaxant and anti-inflammatory agent. There were no postoperative infections of the mesh and no mesh had to be removed secondary to infection or pain.

Late adverse events at a median (range) follow-up of 62 (41–92) months are shown in Table 4. Eight patients (8%) had a mesh extrusion due to healing defects. This complication occurred at 6 weeks to 4 months after surgery. In six cases local oestrogen therapy was sufficient treatment. In the two other patients surgery was required under local anaesthesia, and involved a minor procedure to excise the exposed mesh (the course was favourable, with no recurrences with a follow-up of >4 years). There was retraction of the prosthesis in six patients (6%), the diagnoses being made clinically by digital palpation in all cases. De novo dyspareunia was reported by two patients (2%) and these patients had an associated posterior repair with mesh. We also report two cases of de novo urinary incontinence (2%) and two of chronic pelvic pain (2%).

At 36 months after surgery all patients were available for a physical assessment and were able to complete both the symptoms and QoL questionnaires; there were no withdrawals during this period. The anatomical cure rate for cystocele was 93%, 43 patients (41%) having no

**Table 3** Urinary symptoms before surgery, showing the correlation between clinical findings and urodynamic assessment.

Clinical findings	Urodynamic assessment								
	All	(a)	(b)	(c)	(d)	(a + c)	(a + d)	(b + d)	Normal
SUI	29	14	5	0	4	2	2	2	0
Urgency	37	3	0	0	25	0	2	4	3
Dysuria	20	0	0	2	0	0	0	0	18
Normal	19	0	0	2	3	0	0	0	14

(a) Urethral hypermobility, (b) sphincter deficiency, (c) bladder hypocontractility, (d) detrusor overactivity.

**Table 4** Immediate and late adverse events.

Adverse event	n (%)
<b>Intraoperative complications</b>	
Bladder injury	0
Rectal injury	0
Conversion	0
Blood transfusion	0
<b>Early postoperative complications (&lt; 30 days)</b>	
Fever	7 (7)
Haematoma	0
Urinary retention	6 (6)
De novo urinary incontinence	2 (2)
Mesh infection	0
Thrombophlebitis of the lower limb	1 (1)
<b>Late complications (≥ 30 days)</b>	
Mesh extrusion	8 (8)
Mesh retraction	6 (6)
De novo dyspareunia	2 (2)
Chronic pelvic pain	2 (2)
Chronic pain at the inner side of the thigh	1 (1)
Re-intervention related to pain or mesh erosion	0

**Table 5** Stratification of prolapse (Baden and Walker) before and after surgery.

Prolapse	Stage, n (%)				
	0	I	II	III	IV
<b>Anterior compartment</b>					
Before	0	0	10 (10)	80 (76)	15 (14)
36 months after	43 (41)	55 (52)	7 (7)	0	0
<b>Apical compartment</b>					
Before	8 (8)	15 (14)	25 (24)	39 (37)	18 (17)
36 months after	48 (46)	46 (44)	11 (11)	0	0
<b>Posterior compartment</b>					
Before	18 (17)	19 (18)	44 (42)	18 (17)	6 (6)
36 months after	25 (24)	72 (69)	9 (9)	0	0

cystocele, and 55 (52%) having a stage I cystocele. There were seven surgical failures (recurrent cystoceles; 7%), all at stage II (Table 5). Four of these recurrences were at 3–5 months after the treatment of a post-hysterectomy prolapse. No re-operation was done in these cases and only local oestrogen therapy was prescribed.

There was an improvement in the subjective prolapse symptoms after surgery. A favourable outcome was reported in all patients who had a TOT (no urinary incontinence or other urinary symptoms were reported). All the scores for the QoL and sexuality questionnaires also improved, as shown in Table 6. The overall satisfaction score (VAS) was 71.4%. Judging the results on the association of the four most common symptoms

**Table 6** Pelvic discomfort, symptoms, QoL and sexuality scores before and after surgery.

Assessment	Before	36-months	P
Pelvic discomfort VAS (0–10)	7.6	1.8	< 0.05
<b>PFDI</b>			
<b>POPDI</b>			
(0–100)	51.02	19.04	< 0.05
Anterior (0–100)	23.81	10.01	< 0.05
Posterior (0–100)	35.98	19.67	< 0.05
<b>CRADI</b>			
Obstructive (0–100)	35.25	14.00	< 0.05
Incontinence (0–100)	10.22	7.19	NS
Pain/irritative (0–100)	30.12	14.11	< 0.05
Rectal prolapse (0–100)	28.37	2.10	< 0.05
<b>UDI</b>			
Irritative symptoms (0–100)	38.28	11.23	< 0.05
Obstructive/discomfort (0–100)	43.22	8.39	< 0.05
Stress symptoms (0–100)	22.78	3.24	< 0.05
<b>PFDIQ</b>			
<b>POPIQ</b>			
Physical activity (25–100)	38.15	26.10	< 0.05
Social relationships (25–100)	33.55	26.50	< 0.05
Travel (25–100)	28.88	27.10	NS
Emotional health (25–100)	33.28	25.22	< 0.05
<b>CRAIQ</b>			
Physical activity (25–100)	29.66	26.31	NS
Social relationships (25–100)	25.11	26.10	NS
Travel (25–100)	28.33	26.10	NS
Emotional health (25–100)	28.11	27.50	NS
<b>UIQ</b>			
Physical activity (25–100)	44.28	24.48	< 0.05
Social relationships (25–100)	37.40	34.05	NS
Travel (25–100)	42.59	22.32	< 0.05
Emotional health (25–100)	51.25	25.33	< 0.05
<b>PPISQ-12<sup>a</sup></b>	27.50	36.40	< 0.05

POPDI, pelvic organ prolapse distress inventory; CRADI, colorectal and anal distress inventory; UDI, urinary distress inventory; POPIQ, pelvic organ prolapse impact questionnaire; CRAIQ, colorectal and anal impact questionnaire; UIQ, urinary impact questionnaire. NS, not significant.

<sup>a</sup> Completed by 74 patients.

(vaginal globus, pelvic heaviness, urinary symptoms, dyspareunia), the success rate was 72.9%. There was a significant correlation between the success rate and satisfaction score ( $P < 0.001$ ).

## Discussion

The use of mesh in vaginal prolapse surgery combines the advantages of abdominal sacral colpopexy with the low morbidity of vaginal surgery. The transobturator route was described by Delorme [11] in 2001 for the treatment of SUI, and then extended to genital prolapse. It is a minimally invasive surgery where the pelvic fasciae are spared [12]. The obturator foramen provides good security for the surgeon, and thus there is no major nerve or vascular elements in contact with the mesh [13,14].

Tayrac et al. [15] were among the first to use this route. They used a two-arm mesh, leaving its apical part in contact with the bladder unattached. The mesh could then retract its middle portion, and lead to long-term complications such as exposure, chronic pelvic pain, dyspareunia or recurrence of cystocele. Tayrac et al. [15] reported that the high rate of recurrence in the series could be attributed to this technique. The four-arm mesh technique was first described in 2004 by Palma et al. [16]. The dissection is the same as in the technique using two-arm mesh, and the bleeding risk is not increased. The result is a mesh that covers the whole extent of the bladder [17]. Intraoperative complications of transobturator route are mainly bleeding, and pelvic organ injuries (urethra, bladder, rectum or vagina) are exceptional [18,19]. No intraoperative incident such as haemorrhage or organ injury was reported in the present series.

For the anatomical results several studies have shown the superiority of prosthetic surgery over traditional surgery, with an anatomical cure rate of 75–100% in the former [20]. Recurrence might be due to retraction of the mesh, failure of prosthetic support or to ageing of the patients [19]. We also think that the recurrence of cystocele is connected with a secondary displacement of the mesh. Indeed, mesh integration is a necessary condition for the correction of cystocele, and this is usually obtained in a few weeks. During this period a minimum of displacement is unavoidable. This is why some authors [21] suggest fixing the prosthesis after vaginal dissection with non-absorbable sutures, to cover the defect and prevent dislocation and deformation of the prosthesis. In case of recurrence, the removal of the prosthesis might be necessary and re-operation generally requires a different surgical technique. In the present series the anatomical success rate was 93%, and all recurrences (7%) were at stage II, with no re-operations.

All studies agree that there is a significant improvement in functional symptoms after prosthetic surgery.

However, these results are similar to those of traditional surgery [22]. In the present series a significant improvement was reported on most of the subjective prolapse symptoms after surgery. Considering the results for the four most common symptoms, the success rate was 73%, and the overall satisfaction score was 71%.

Sexuality after vaginal prosthetic surgery has been the subject of several studies, with controversial results. The optimal time for sexual assessment should be at 6–12 months after surgery. It should ideally involve the partner, and the results must be considered in relation to the general population of the same age [23]. Khandwala et al. [24] and Eboue et al. [25] used the questionnaire on sexuality (PISQ-12) after surgery. The scores were improved in 22.9% and 24.4%, respectively, and unchanged in 85.7% and 57.8%. Surgery improved dyspareunia significantly in the series of Khandwala et al. [24] (48.1% before vs. 7.4% after surgery). The improvement in dyspareunia was also significant in the present series (86.6% before vs. 11% after). De novo dyspareunia can complicate vaginal surgery even if no meshes are used. Indeed, Carey et al. [26], in a randomised study comparing functional outcomes between the classic treatment of vaginal cystocele and after interposition of polypropylene mesh, found a significantly higher rate of dyspareunia in the group having a classic colporrhaphy. De novo dyspareunia was reported in 9–20% of patients after the treatment of cystocele with meshes [27]. We reported two cases of de novo dyspareunia (2%). The results of the present QoL and sexuality questionnaires were encouraging for the use of the type of mesh that we chose.

Urinary emergencies are often associated with cystocele. Symptomatic SUI is more associated with moderate prolapse, whilst an important prolapse is more often associated with obstructive phenomena. Eboue et al. [25], after a follow-up of 34 months, reported a significant improvement in SUI after cystocele was cured with a four-arm transobturator mesh. Long et al. [28] combined a tension-free vaginal tape (TVT) or TOT in patients with SUI. They reported a significant improvement in all urinary symptoms (SUI, urgency and dysuria). They recommended TOT rather than TVT due to the horizontal position of the strip, resulting in less postoperative dysuria. In all the present patients there was a significant improvement in dysuria (20 before vs. two after surgery,  $P < 0.05$ ) and urinary emergencies (37 vs. 12, respectively,  $P < 0.05$ ). All patients with SUI were surgically treated by the combination of a TOT and cystocele repair. The improvement in SUI was significant (19 vs. two, respectively,  $P < 0.05$ ). In our experience we never try to treat SUI by modifying the positioning of the ventral part of the mesh to be at the mid-urethral site, because we consider that the risk of mesh retraction or displacement might influence the outcome of the correction of SUI.



The most serious complication related to mesh is retraction. It can cause failure by restricting support areas, and secondary pain and dyspareunia caused by increased tension on the structures. The frequency of retractions is difficult to assess as there is no clear definition, but it is reported to be 11.7–17% [29]. In the present series the prosthesis retracted in six patients (6%). The retraction mechanism might be linked to several factors that lead to peri-prosthetic fibrosis. The occurrence of retraction depends on the mesh and on the inflammatory process after surgery. Its prevention requires the use of meshes with lighter composite materials. The diagnosis is made clinically or by transvaginal ultrasonography [22,30].

The exposure of the mesh is another specific complication of prosthetic surgery. Exposure occurs most frequently during the second month after surgery [21]. It is usually asymptomatic and discovered in the postoperative examination. However, it can cause minimal bleeding or vaginal discharge. The main cause of mesh exposure is colpectomy. Excision of the 'excess' of the vagina is usually done for aesthetic purposes. Vaginal tension sutures cause fragile scarring, increasing the risk of exposure [21]. In addition to colpectomy the type of incision seems to be important, mainly a T-incision (incision of Crossen) for hysterectomy [17]. Sergeant et al. [17] and Eboue et al. [25] also recommended that a 'systematic' hysterectomy not be used when treating genital prolapse. Bafghi et al. [31] proposed a circular incision of the anterior cervix with vesico-vaginal retrograde dissection instead of the conventional vertical colpotomy. Thus the insertion of the mesh is not located next to the incision. These authors [17,25,31] reported the following rates of exposure, respectively: 16%, 6.5% and 2%. In the present series the vertical colpotomy and T colpotomy, if associated with hysterectomy, gave an exposure rate of 7.6%. All patients with exposure had a concomitant hysterectomy. Lack of oestrogen also represents a risk factor for mesh exposure, thus some authors recommend systematic local oestrogen therapy before and after surgery [32,33]. Early sexual intercourse is another risk factor for exposure. Letouzey et al. [19] recommended a period of abstinence of 6 weeks after surgery. The treatment of mesh exposure is based on local oestrogen therapy to improve the trophicity of the vagina, associated with partial excision of the protruding portion of the mesh. However, if conservative treatment fails, surgical revision with total removal of the mesh might be necessary (1.5% of cases in the series of Letouzey et al. [19]). In the present series local oestrogen therapy was sufficient for six patients, and colpectomy with a partial excision was necessary in two. No patient required complete removal of the prosthesis.

Infections have become exceptional with the new implants. When they complicate an exposure of the

mesh, more than half are treated medically. If infection persists beyond 2 months excision of the implant is required [34]. The prosthetic infection rate is 0–8% with or without previous exposure of the mesh [35]. A case of pelvic cellulitis was reported by Flood et al. [36] in 1998, and Cosson et al. [37] in 2005. Myers et al. [38] reported a case of pelvic abscess.

Chronic pelvic pain can also complicate prosthetic surgery. Pain is usually localised on the buttock, or at the groin [39]. Vaiyapuri et al. [40] reported 10.4% of patients had buttock pain and 22.6% had pain in the inner side of the thigh. The pain is due to the passage of the needle through the adductor muscles. Excessive traction on the arm of the mesh can also cause chronic vaginal pain. If pain persists beyond 6 months removal of the prosthesis becomes inevitable. Diagnosis and early treatment are necessary. In case of delay, even after removal of the prosthesis, the pain can persist due to irreversible nerve damage [21]. In the present series one patient reported chronic pain at the inner side of the thigh, but the course was favourable under anti-inflammatory treatment.

There are several limitations to the present study. The lack of a control arm and the relatively few patients could affect the statistical results and do not enable us to draw firm conclusions; more randomised studies involving many more patients are needed. We could not have precise data about the severity of SUI before surgery and the outcome of patients with mixed urinary incontinence after cystocele repair. On analysis of the results, demographic factors, which play an important role in recurrences and might explain postoperative complications, were not sufficiently investigated for correlation with the success or failure rates.

In conclusion, if the guidelines and precautions are followed, vaginal prosthetic surgery for genitourinary prolapse has shown long-term benefits. The transobturator route has a special place because of its low morbidity, excellent reproducibility and remarkable efficiency. Guidelines are now well established and involve even large cystoceles of stage III after the failure of other treatment methods. This route provides excellent results both anatomically and functionally. However, complications are not negligible and some are specific to prosthetic surgery. The first choice of mesh is currently the lightweight macroporous monofilament polypropylene mesh, but other materials, including composite and biological meshes are beginning to take their place on the market. Randomised studies comparing these materials with each other and with polypropylene are needed to improve the outcomes and reduce complications.

#### **Conflict of interest**

None.

## Source of funding

None.

## References

- [1] De Lancey JOL, Richardson AC. Anatomy of genital support. *Clin Obstet Gynecol* 1993;**36**:19–33.
- [2] Richardson AC, Lyon JB, Williams NL. A new look at pelvic relaxation. *Am J Obstet Gynecol* 1976;**126**:568–73.
- [3] Olsen A, Smith V, Bergstrom J, Colling JC, Clark AL. Epidemiology of surgically managed pelvic organ prolapse and urinary incontinence. *Obstet Gynecol* 1997;**89**:501–6.
- [4] Debodinance P, Amblard J, Faton B, Cosson M, Jacquelin B. The prosthetic kits in the prolapse surgery: is it a gadget? *J Gynecol Obstet Biol Reprod* 2007;**36**:267–75.
- [5] Sand PK, Koduri S, Lobel RW, Winkler HA, Tomezsko J, Culligan PJ, et al. Prospective randomized trial of polyglactin 910 mesh to prevent recurrence of cystoceles and rectoceles. *Am J Obstet Gynecol* 2001;**184**:1357–62.
- [6] Julian TM. The efficacy of Marlex mesh in the repair of severe, recurrent vaginal prolapse of the anterior midvaginal wall. *Am J Obstet Gynecol* 1996;**175**:1472–5.
- [7] Baden WF, Walker TA, Lindsay HJ. The vaginal profile. *Tex Med J* 1968;**64**:56–8.
- [8] De Tayrac R, Chauveaud-Lambling A, Fernandez D, Fernandez H. Quality of life instruments for women with pelvic organ prolapsed. *J Gynecol Obstet Biol Reprod* 2003;**32**:503–7.
- [9] Rogers RG, Coates KW, Kammerer-Doak D, Khalsa S, Qalls C. A short form of the pelvic organ prolapse/urinary incontinence sexual questionnaire (PISQ-12). *Int Urogynecol J Pelvic Floor Dysfunct* 2003;**14**:164–8.
- [10] Schäfer W, Abrams P, Liao L. International continence society good urodynamic practices. uroflowmetry, filling cystometry, and pressure-flow studies. *Neurol Urodyn* 2002;**21**:261–74.
- [11] Delorme E. Transobturator urethral suspension. mini-invasive procedure in the treatment of stress urinary incontinence in women. *Prog Urol* 2001;**11**:1306–13.
- [12] Sergent F, Sentilhes L, Resch B, Diguët A, Verspyck E, Marpeau L. Prosthetic repair of genito-urinary prolapses by the transobturator infracoccygeal hammock technique: medium-term results. *J Gynecol Obstet Biol Reprod* 2007;**36**:459–67.
- [13] Delorme E, Droupy S, De Tayrac R, Delmas V. Transobturator tape (Uratape). A new minimally invasive method in the treatment of urinary incontinence in women. *Prog Urol* 2003;**13**:656–9.
- [14] Delmas V. Anatomical risks of transobturator suburethral tape in the treatment of female stress urinary incontinence. *Eur Urol* 2005;**48**:793–8.
- [15] De Tayrac R, Deffieux X, Gervaise A, Chauveaud-Lambling A, Fernandez H. Long-term anatomical and functional assessment of transvaginal cystocele repair using a tension-free polypropylene mesh. *Int Urogynecol J Pelvic Floor Dysfunct* 2006;**17**:483–8.
- [16] Palma P, Rane A, Riccetto C, Herrmann V, Dambros M, Tarazona A. Transobturator correction of cystocele. *Actas Urol Esp* 2005;**29**:89–92.
- [17] Debodinance P, Berrocal J, Clavé H, Cosson M, Garbin O, Jacquelin B, et al. Changing attitudes on the surgical treatment of urogenital prolapse: birth of the tension-free vaginal mesh. *J Gynecol Obstet Biol Reprod* 2004;**33**:577–88.
- [18] Maher C, Feiner B, Bessler K, Schmid C. Surgical management of pelvic organ prolapse in women. *Cochrane Database Syst Rev* 2010;CD004014.
- [19] Deffieux X, Savary D, Letouzey V, Sentilhes L, Agostini A, Mares P, et al. Prevention of the complications related to the use of prosthetic meshes in prolapse surgery: Guidelines for clinical practice – literature review. *J Gynecol Obstet Biol Reprod* 2011;**40**:827–50.
- [20] Feldner Jr PC, Castro RA, Cipelotti LA, Delroy CA, Sartori MJ, Girão MJ. Anterior vaginal wall prolapse: a randomized controlled trial of SIS graft versus traditional colporrhaphy. *Int Urogynecol J Pelvic Floor Dysfunct* 2010;**21**:1057–63.
- [21] Von Theobald P. Place of mesh in vaginal surgery, including its removal and revision. *Best Pract Res Clin Obstet Gynecol* 2011;**25**:197–203.
- [22] Barber MD, Brubaker L, Nygaard I, Wheeler 2nd TL, Schaffer J, Chen Z, et al. Defining success after surgery for pelvic organ prolapse. *Obstet Gynecol* 2009;**114**:600–9.
- [23] Faton B. Sexual outcome after pelvic organ prolapse surgery. *Prog Urol* 2009;**19**:1037–59.
- [24] Khandwala S, Jayachandran C. Transvaginal mesh surgery for pelvic organ prolapse-proliferation: a prospective clinical trial. *Int Urogynecol J* 2011;**22**:1405–11.
- [25] Eboue C, Marcus-Braun N, Von Theobald P. Cystocele repair by transobturator four arms mesh: monocentric experience of first 123 patients. *Int Urogynecol J* 2010;**21**:85–93.
- [26] Carey M, Higgs P, Goh J, Lim J, Leong A, Krause H, et al. Vaginal repair with mesh versus colporrhaphy for prolapse: a randomised controlled trial. *BJOG* 2009;**116**:1380–6.
- [27] Blandon RE, Gebhart JB, Trabuco EC, Klingele CJ. Complications from vaginally placed mesh in pelvic reconstructive surgery. *Int Urogynecol J* 2009;**20**:523–31.
- [28] Long CY, Hsu CS, Jang MY, Liu CM, Chiang PH, Tsai EM. Comparison of clinical outcome and urodynamic findings using “Perigee and/or Apogee” versus “Prolift anterior and/or posterior” system devices for the treatment of pelvic organ prolapse. *Int Urogynecol J* 2011;**22**:233–9.
- [29] Milani AL, Withagen MI, Vierhout ME. Trocar-guided total tension-free vaginal mesh repair of post-hysterectomy vaginal vault prolapsed. *Int Urogynecol J* 2009;**20**:1203–11.
- [30] Lucot JP, Bot-Robin V, Girodet G, Rubod C, Boulanger L, Dedet B, et al. Place du matériel prothétique dans le traitement du prolapsus par voie vaginale. *Gynecol Obstet Biol Reprod* 2011;**39**:232–44.
- [31] Bafghi A, Lannelli A, Verger S, Novelas S, Amiel J, Gugenheim J, et al. Transvaginal repair of genital prolapse with Prolift™: evaluation of safety and learning curve. *J Gynecol Obstet Biol Reprod* 2009;**38**:77–82.
- [32] Ahtari C, Hiscock R, O'Reilly BA, Schierlitz L, Dwyer PL. Risk factors for mesh erosion after transvaginal surgery using polypropylene (Atrium) or composite polypropylene/polyglactin 910 (Vypro II) mesh. *Int Urogynecol J Pelvic Floor Dysfunct* 2005;**16**:389–94.
- [33] Bader G, Fauconnier A, Roger N, Heitz D, Ville Y. Cystocele repair by vaginal approach with a tension-free transversal polypropylene mesh. Technique and results. *Gynecol Obstet Fertil* 2004;**32**:280–4.
- [34] Niro J, Philippe AC, Jaffeux P, Amblard J, Velemir L, Savary D, et al. Postoperative pain after transvaginal repair of pelvic organ prolapse with or without mesh. *Gynecol Obstet Fertil* 2010;**38**:648–52.
- [35] Simsman AJ, Luber KM, Menefee SA. Vaginal paravaginal repair with porcine dermal reinforcement. Correction of advanced anterior vaginal prolapse. *Am J Obstet Gynecol* 2006;**195**:1832–6.
- [36] Flood CG, Drutz HP, Waja L. Anterior colporrhaphy reinforced with Marlex mesh for the treatment of cystoceles. *Int Urogynecol J Pelvic Floor Dysfunct* 1998;**9**:200–4.

- [37] Caquant F, Collinet P, Deruelle P, Lucot JP, Cosson M. Perineal cellulitis following trans-obturator sub-urethral tape Uratape®. *Eur Urol* 2005;**47**:108–10.
- [38] Rardin CR, Moore R, Ward RM, Myers DL. Recurrent thigh abscess with necrotizing fasciitis from a retained transobturator sling segment. *J Minim Invasive Gynecol* 2009;**16**:84–7.
- [39] Moore RD, Miklos JR. Vaginal repair of cystocele with anterior wall mesh via transobturator route: efficacy and complications with up to 3-year followup. *Adv Urol* 2009;743–831.
- [40] Vaiyapuri GR, Han HC, Lee LC, Tseng LA, Wong HF. Use of the gynecare prolift system in surgery for pelvic organ prolapse: 1-year outcome. *Int Urogynecol J* 2011;**22**:869–77.